

Ophthalmic Genetics

ISSN: 1381-6810 (Print) 1744-5094 (Online) Journal homepage: www.tandfonline.com/journals/iopg20

Do MEFV genotypes shape retinal and choroidal microvascular involvement in familial Mediterranean fever?

Şule Barman Kakil, Mete Pekdiker & Hasan Uğur Yıldız

To cite this article: Şule Barman Kakil, Mete Pekdiker & Hasan Uğur Yıldız (01 Jun 2026): Do MEFV genotypes shape retinal and choroidal microvascular involvement in familial Mediterranean fever?, Ophthalmic Genetics, DOI: 10.1080/13816810.2026.2674254

To link to this article: https://doi.org/10.1080/13816810.2026.2674254

Published online: 01 Jun 2026.

Submit your article to this journal

View related articles

View Crossmark data

Full Terms & Conditions of access and use can be found at
https://www.tandfonline.com/action/journalInformation?journalCode=iopg20

OPHTHALMIC GENETICS
https://doi.org/10.1080/13816810.2026.2674254

Taylor & Francis
by informa

RESEARCH ARTICLE

Check for updates

Do MEFV genotypes shape retinal and choroidal microvascular involvement in familial Mediterranean fever?

Şule Barman Kakil[a], Mete Pekdiker[b], and Hasan Uğur Yıldız[a]

[a]Department of Ophthalmology, Tayfur Ata Sokmen Faculty of Medicine, Mustafa Kemal University, Antakya, Türkiye; [b]Department of Internal Medicine-Rheumatology, Tayfur Ata Sokmen Faculty of Medicine, Mustafa Kemal University, Hatay, Türkiye

ABSTRACT

Purpose: To evaluate retinal and choroidal microvascular alterations in patients with Familial Mediterranean Fever (FMF) and to investigate their associations with MEFV genotype and clinical phenotype using optical coherence tomography angiography (OCTA).

Methods: In this cross-sectional study, 130 FMF patients (260 eyes) and 120 age- and sex-matched healthy controls (240 eyes) underwent OCTA imaging. Patients were stratified according to MEFV genotype and clinical phenotype, including amyloidosis, arthritis, serositis, and erysipelas-like erythema. Vessel density parameters in the superficial and deep capillary plexus (SCP and DCP), foveal avascular zone (FAZ), retinal nerve fiber layer (RNFL), choriocapillaris flow area, and optic nerve head parameters were analyzed using linear mixed-effects models adjusted for age and sex.

Results: Compared with controls, FMF patients demonstrated significantly reduced DCP vessel density in the whole image, parafoveal, and perifoveal regions, whereas SCP, FAZ, RNFL, and optic nerve head parameters were comparable. Within the FMF cohort, age was the strongest predictor of reduced DCP vessel density and choriocapillaris flow. M694V carriage and amyloidosis were independently associated with lower parafoveal and perifoveal DCP vessel density.

Conclusions: FMF is associated with selective deep retinal microvascular impairment, particularly in patients carrying the M694V mutation and in those with amyloidosis. OCTA-derived DCP parameters may serve as non-invasive biomarkers of systemic microvascular involvement in FMF.

ARTICLE HISTORY
Received 6 October 2025
Revised 1 May 2026
Accepted 10 May 2026

KEYWORDS
Familial Mediterranean fever (FMF); MEFV mutations; optical coherence tomography angiography (OCTA); retinal microvasculature; deep capillary plexus (DCP)

1. Introduction

Familial Mediterranean fever (FMF) is the most common monogenic autoinflammatory disease, predominantly affecting populations around the Mediterranean basin, including Turks, Armenians, Jews, and Arabs. It is caused by mutations in the MEFV gene, which encodes pyrin, a key regulator of the inflammasome pathway. Gain-of-function mutations in pyrin lead to inappropriate caspase-1 activation and excessive IL-1β production, resulting in recurrent attacks of fever, serositis, arthritis, and erysipelas-like erythema. Although classically inherited in an autosomal recessive manner, clinical expression may also occur in heterozygous carriers, suggesting the role of modifier genes and epigenetic factors (1).

FMF has become a paradigmatic model of systemic autoinflammation, with well-documented geographic distribution and genotype—phenotype variability (2). Large-scale multicenter studies from Turkey have shown that M694V is the predominant mutation, followed by M680I and V726A (3). M694V, particularly in homozygous or compound heterozygous forms, is associated with early-onset, severe disease and amyloidosis, whereas variants such as V726A and E148Q are generally linked to milder phenotypes (1). Recent advances also indicate that even single heterozygous mutations may trigger clinically significant inflammation through environmental or epigenetic modifiers (4).

Although ocular manifestations are more commonly described in spondyloarthritis, evidence now suggests that monogenic autoinflammatory diseases, including FMF, may also involve the eye. Subclinical alterations in the retinal microvasculature could reflect systemic inflammatory dysregulation, even in the absence of overt ophthalmic symptoms. Advanced imaging methods such as Optical Coherence Tomography Angiography (OCTA) enable detection of these subtle change (5). Preliminary OCTA-based studies have demonstrated that FMF patients may exhibit significantly reduced vascular density in the deep capillary plexus (DCP) and increased retinal thickness parameters compared with controls (6). while others focusing only on M694V-positive cases found no significant differences, likely due to limited sample size and absence of phenotype stratification (7). Given the clinical heterogeneity of FMF, phenotype-based stratification was incorporated to assess whether specific systemic manifestations are associated with differential ocular microvascular involvement.

Collectively, these findings suggest that ocular microvascular changes may parallel systemic inflammatory burden, yet current data remain inconsistent. Collectively, these findings suggest that ocular microvascular changes may parallel systemic inflammatory burden, yet current data remain inconsistent.

CONTACT Şule Barman Kakil sule.barmankakil@mku.edu.tr Department of Ophthalmology, Tayfur Ata Sökmen Faculty of Medicine, Hatay Mustafa Kemal University, Antakya, Hatay 31060, Türkiye

© 2026 Taylor & Francis Group, LLC

Despite increased recognition of systemic inflammation's ocular impact, data on FMF-related eye involvement are still sparse. Most reports are case-based and lack standardized imaging or subgroup analysis. This diagnostic blind spot may result in missed detection of important ocular findings. Addressing this gap requires sensitive imaging techniques and stratified analyses based on genotype and phenotype to uncover hidden markers of inflammatory activity (8).

The present study aimed to comprehensively evaluate retinal and choroidal microvascular alterations in a large FMF cohort using OCTA, in comparison with an age- and sex-matched healthy control group. By integrating clinical phenotypes and MEFV mutation profiles, we sought to determine whether distinct genetic and clinical subgroups exhibit characteristic ocular vascular patterns and whether these alterations differ from normative microvascular parameters. To our knowledge, this is the first study to combine genotype—phenotype correlations with a matched control comparison and multimodal ocular imaging in FMF, providing novel insights into the systemic microvascular burden of this autoinflammatory disease.

2. Material- methods

2.1. Patients selection

Adult patients with a confirmed diagnosis of FMF, recruited from the Rheumatology and Ophthalmology Departments of Hatay Mustafa Kemal University, were retrospectively analyzed. FMF was diagnosed according to the Tel-Hashomer criteria (9).

Inclusion criteria were: age ≥18 years, diagnosis confirmed by two rheumatologists, clinical remission under stable colchicine and/or biologic (IL-1 inhibitor) therapy, and availability of high-quality OCTA scans.

All 130 patients contributed bilateral OCTA scans (total 260 eyes). The predefined minimum signal strength index (SSI) threshold for image inclusion was ≥ 40, in accordance with device recommendations. Although this threshold was uniformly applied, the majority of scans demonstrated higher signal strength (SSI ≥50, most ≥60), reflecting overall high image quality. Only a small number of FMF eyes ($n = 7$) had SSI <50, and sensitivity analyses excluding these scans did not materially alter the results, confirming that the findings were robust to SSI variation.

Exclusion criteria included history of ocular trauma or surgery, refractive error >±3.0 D, glaucoma, macular degeneration, other retinal/choroidal vascular diseases, autoimmune disorders other than FMF, systemic therapies other than colchicine, and poor-quality OCTA images. Patients were stratified by genotype (M694V homozygous, heterozygous, compound heterozygous, other variants, mutation-negative) and phenotype (amyloidosis, arthritis, serositis, erysipelas-like erythema). To reduce the confounding effect of acute inflammation on OCTA metrics, only patients in clinical remission under stable colchicine and/or IL-1 inhibitor therapy were included. An age- and sex-matched healthy control cohort ($n = 120$; 240 eyes) was included. Controls were recruited from individuals undergoing routine ophthalmic evaluation with no history of systemic inflammatory disease or ocular pathology and with refractive error within ±3.0 diopters. OCTA imaging in controls was performed using the same AngioVue protocol and acquisition parameters. Only scans with SSI ≥50 and without motion or segmentation artifacts were included. Although the AngioVue system incorporates built-in normative reference data, we elected to include an external matched control cohort to provide a directly comparable dataset under identical imaging conditions.

2.2. Ophthalmic examination

All participants underwent comprehensive ophthalmic examination including best-corrected visual acuity (BCVA), slit-lamp biomicroscopy, intraocular pressure measurement, and dilated fundus examination. Examinations were performed by two masked ophthalmologists. Optical Coherence Tomography Angiography was performed using the AngioVue system (RTVue XR Avanti, Optovue Inc., Fremont, CA, USA), a spectral-domain OCTA device based on the split-spectrum amplitude decorrelation angiography (SSADA) algorithm. To minimize diurnal variation, all scans were obtained between 09:00 and 11:00 a.m.

Two standardized scan protocols were used:

Macula: 6 × 6 mm high-definition scan centered on the fovea.

Optic nerve head (ONH): 4.5 × 4.5 mm scan centered on the optic disc.

Only scans meeting the predefined SSI threshold (≥40 for FMF patients; ≥50 for controls) and without motion or segmentation artifacts were included. Macular scans were analyzed using the built-in AngioVue software with automatic segmentation of the superficial and deep capillary plexuses. The superficial capillary plexus (SCP) was defined from the internal limiting membrane (ILM) to the inner plexiform layer (IPL), whereas the deep capillary plexus (DCP) extended from the inner nuclear layer (INL) to the outer plexiform layer (OPL). All scans were carefully reviewed for segmentation accuracy, and images demonstrating segmentation errors were excluded from analysis. Vessel density measurements were obtained from four concentric regions within the 6 × 6 mm macular scan: the foveal region (central 1-mm circle), the parafoveal region (1–3 mm annulus), the perifoveal region (3–6 mm annulus), and the whole image area. The foveal avascular zone (FAZ) area was automatically calculated by the device software. In addition, choriocapillaris flow area (CCFA) and outer retina flow area (ORFA) were quantified within the central 1-mm zone.

Optic nerve head (ONH) parameters were obtained from 4.5 × 4.5 mm scans centered on the optic disc. Vessel density metrics included inside-disc vessel density, peripapillary vessel density measured within a 4.5-mm diameter circular region, and whole-disc vessel density. Structural parameters included the cup-to-disc (C/D) ratio and retinal nerve fiber layer (RNFL) thickness, measured along a standardized 3.4-mm circular scan around the optic disc. All measurements were obtained from both eyes in all participants.This study was conducted and reported in accordance with the STROBE

(Strengthening the Reporting of Observational Studies in Epidemiology) guidelines.

2.3. Statistical analysis

Because both eyes were analyzed (total 260 eyes), inter-eye correlation was addressed using linear mixed-effects models with subject-level random intercepts. This approach allows inclusion of paired-eye data while accounting for within-subject dependency. To confirm the robustness of the findings, generalized estimating equations (GEE) with an exchangeable correlation structure were also applied, yielding comparable results.The primary outcome was DCP vessel density; secondary outcomes were SCP density, FAZ area, RNFL thickness, choriocapillaris/outer retina flow, and optic disc parameters. Models were adjusted for age and sex. Genotype was examined as M694V carrier (yes/no) and categorical groups; phenotypes (amyloidosis, arthritis, serositis, erysipelas-like erythema) as binary variables. Multicollinearity was assessed using variance inflation factors (VIF), and model assumptions were evaluated through residual diagnostics. Results are reported as β coefficients with 95% CI, with $p < 0.05$ considered significant. A post hoc power analysis was conducted based on the observed effect size for parafoveal DCP vessel density, demonstrating statistical power exceeding 90% at $\alpha = 0.05$. Analyses were performed using SPSS v25.0 and R. The study adhered to the Declaration of Helsinki and was approved by the Hatay Mustafa Kemal University Ethics Committee (Date: 18 June 2025, Meeting no: 08, Decision no: 38); all participants provided written informed consent.

3. Results

Of 145 FMF patients screened, 15 were excluded (poor-quality OCTA $n = 6$, high refractive error $n = 4$, ocular surgery $n = 3$, other autoimmune disease $n = 2$). The final analysis included 130 patients (62 males, 68 females), contributing a total of 260 eyes. The mean age was 34.8 ± 11.2 years (range 18–62), and mean disease duration was 10.3 ± 6.8 years. Baseline demographic, clinical, and treatment characteristics are summarized in Table 1. Regarding genetics, 102 patients (78.5%) carried at least one M694V mutation (homozygous $n = 30$, heterozygous $n = 12$, compound heterozygous $n = 60$), while 12 (9.2%) had other MEFV variants and 16 (12.3%) were negative. The full genotype distribution is provided in Table 2. The vast majority of patients carried M694V mutations, either in homozygous or compound heterozygous form, confirming its central role in FMF genetics. Among compound heterozygotes, M694V/M680I and M694V/V726A were the most frequent combinations, while other variants such as E148Q and R202Q were less common. Notably, a small subset of patients carried non-M694V mutations or tested negative for MEFV variants, underscoring the genetic heterogeneity of FMF within our cohort.

Demographic characteristics did not differ significantly between FMF patients and controls. Compared with controls, FMF patients demonstrated significantly reduced DCP vessel density in the whole image, parafoveal, and perifoveal regions, whereas SCP, FAZ, RNFL, and optic nerve head parameters were comparable between groups. (Table 3) A representative comparison of OCTA images between an FMF patient and a healthy control is presented in Figure 1.

Table 1. Demographic, clinical, and treatment characteristics of FMF patients.

Variable	*n* (%) or mean ± SD (range)
Male sex	62 (47.7)
Female sex	68 (52.3)
Age, years	34.8 ± 11.2 (18–62)
Disease duration, years	10.3 ± 6.8 (1–30)
Amyloidosis	10 (7.7)
Arthritis	62 (47.7)
Serositis	82 (63.1)
Erysipelas-like erythema	28 (21.5)
Treatment	
– Colchicine only	112 (86.2)
– Biologic therapy	18 (13.8)

Values are presented as *n* (%) or mean ± standard deviation (SD; range). FMF, Familial Mediterranean fever.

Table 2. Distribution of MEFV gene mutations in patients with FMF.

Mutation	Patient count (%)
M694V/M694V (homozygous)	30 (23.1)
M694V/- (heterozygous)	12 (9.2)
Compound heterozygous	
– M694V/M680I	15 (11.5)
– M694V/V726A	12 (9.2)
– M694V/E148Q	10 (7.7)
– M694V/R202Q	8 (6.2)
– Other combinations*	15 (11.5)
Other MEFV variants (non-M694V)	12 (9.2)
Negative	16 (12.3)

*Other combinations include less frequent variants such as M680I/V726I, E148Q/R202Q, etc.

Table 3. Demographic and OCTA/OCT parameters in FMF patients and healthy controls.

Parameter	FMF ($n = 130$; 260 eyes)	Control ($n = 120$; 240 eyes)	p value
Age (years)	34.8 ± 11.2	35.1 ± 10.7	0.79
Sex (M/F), *n*	62 / 68	58 / 62	0.93
Spherical equivalent (D)	−0.40 ± 1.25	−0.35 ± 1.20	0.68
Disease duration (years)	10.3 ± 6.8	—	—
SCP VD—whole (%)	46.9 ± 3.2	47.2 ± 3.1	0.34
SCP VD—foveal (%)	18.6 ± 4.0	18.9 ± 3.9	0.41
SCP VD—parafoveal (%)	49.8 ± 3.6	50.1 ± 3.5	0.38
SCP VD—perifoveal (%)	47.6 ± 3.4	47.9 ± 3.3	0.36
DCP VD—whole (%)	48.1 ± 3.5	49.0 ± 3.4	0.006
DCP VD—parafoveal (%)	50.0 ± 3.9	52.1 ± 3.8	<0.001
DCP VD—perifoveal (%)	49.2 ± 3.7	50.6 ± 3.6	0.002
FAZ area (mm^2)	0.31 ± 0.12	0.30 ± 0.11	0.44
RNFL average (μm)	101.2 ± 9.1	102.0 ± 8.7	0.29
CC flow area (CCFA) (mm^2)	2.02 ± 0.18	2.06 ± 0.17	0.08
Outer retina flow area (ORFA) (mm^2)	1.26 ± 0.15	1.27 ± 0.14	0.57
ONH VD—whole disc (%)	50.8 ± 4.8	51.2 ± 4.6	0.33
ONH VD—inside disc (%)	45.6 ± 5.1	46.0 ± 5.0	0.41
Peripapillary VD (%)	54.1 ± 4.5	54.6 ± 4.4	0.22
Cup-to-disc (C/D) ratio	0.34 ± 0.10	0.33 ± 0.10	0.48

Data are presented as mean ± standard deviation (SD) unless otherwise stated.
Between-group comparisons were performed using linear mixed-effects models adjusted for age and sex, accounting for inter-eye correlation.
Abbreviations: SCP, superficial capillary plexus; DCP, deep capillary plexus; VD, vessel density; FAZ, foveal avascular zone; RNFL, retinal nerve fiber layer; CCFA, choriocapillaris flow area; ORFA, outer retina flow area; ONH, optic nerve head.

In the present cohort of 130 FMF patients, phenotype frequencies varied across genotype groups (Figure 2). Among patients with M694V compound heterozygosity, the prevalence of amyloidosis was 3.6%, arthritis 25.5%, serositis 65.5%, and erysipelas-like erythema (ELE) 16.4%. In the M694V heterozygous group, amyloidosis was observed in 8.3%, arthritis in 75.0%, serositis in 100.0%, and ELE in 25.0%. The M694V homozygous group showed amyloidosis in 13.3%, arthritis in 53.3%, serositis in 60.0%, and ELE in 33.3%. Patients with a negative genotype exhibited amyloidosis in 16.7%, arthritis in 70.0%, serositis in 90.0%, and ELE in 40.0%. Those carrying other mutations had no cases of amyloidosis, while arthritis, serositis, and ELE were present in 72.2%, 77.8%, and 38.9%, respectively. Overall, arthritis and serositis demonstrated significant associations with M694V carriage ($p < 0.001$ and $p = 0.015$, respectively), while

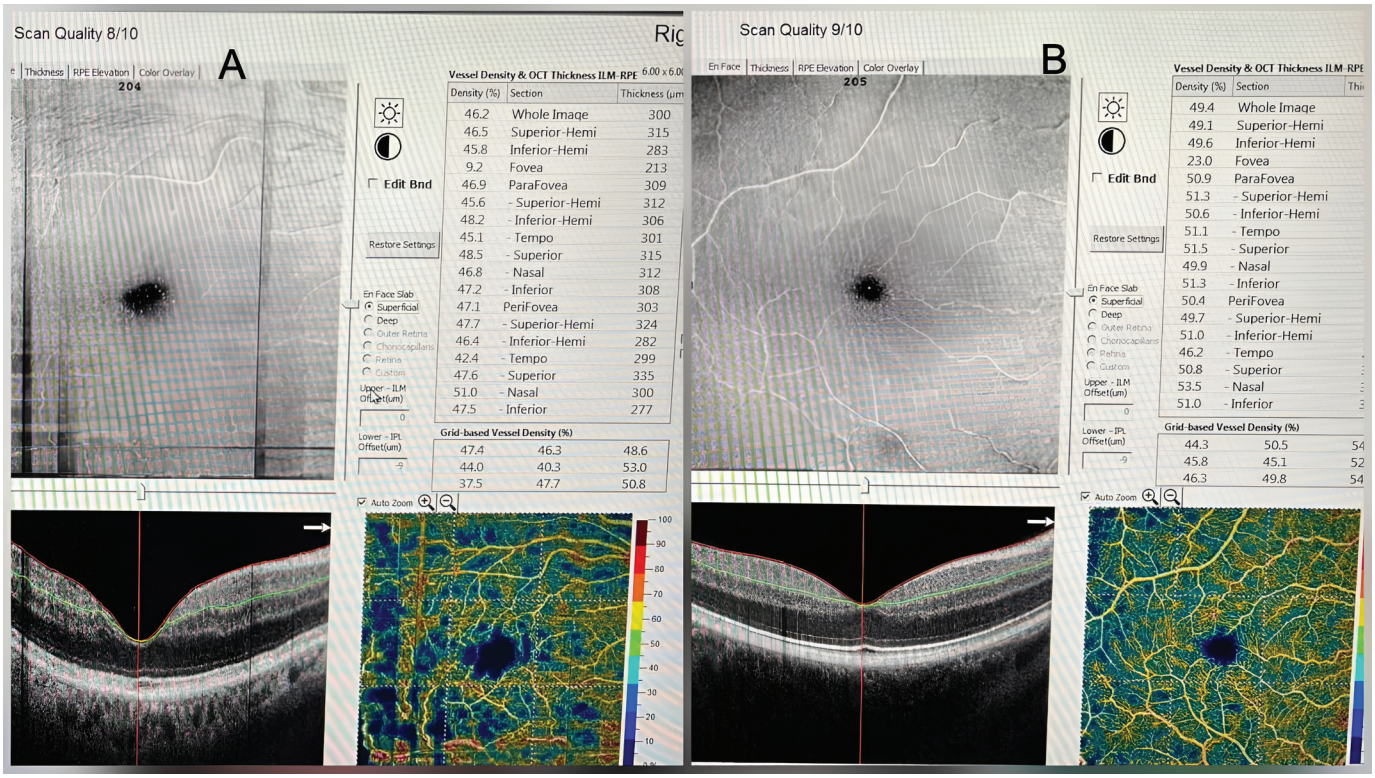

Figure 1. Representative optical coherence tomography angiography (OCTA) images of the deep capillary plexus (DCP) in a healthy control and a patient with familial Mediterranean fever (FMF). (A) Healthy control demonstrating preserved and homogeneous microvascular architecture in the DCP. (B) FMF patient showing reduced vessel density, particularly in the parafoveal region. All images were obtained using a 6 × 6 mm scan protocol and analyzed under identical acquisition parameters.

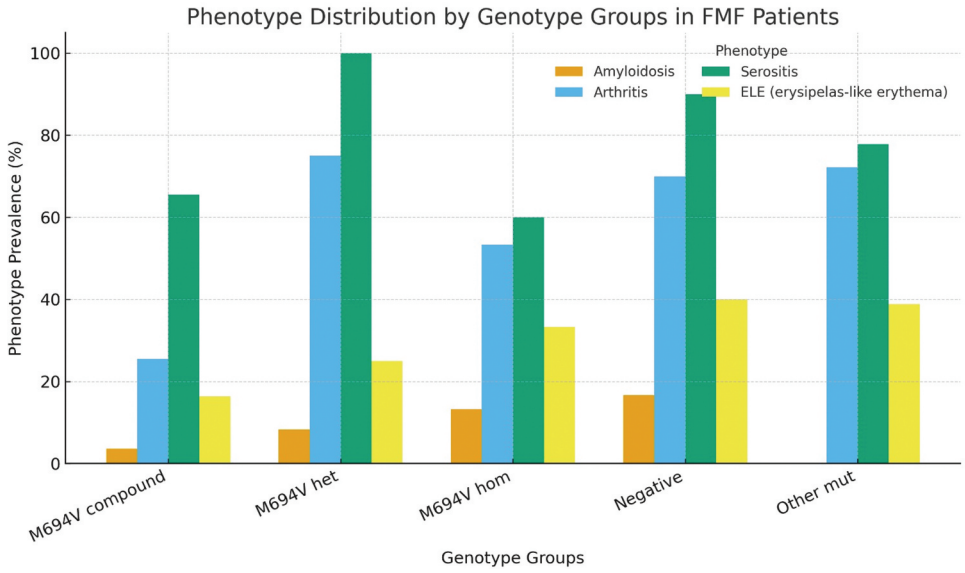

Figure 2. Distribution of clinical phenotypes (amyloidosis, arthritis, serositis, and erysipelas-like erythema [ELE]) across MEFV genotype groups in familial Mediterranean fever (FMF) patients. Phenotype prevalence is expressed as percentages within each genotype subgroup (M694V compound heterozygous, M694V heterozygous, M694V homozygous, mutation-negative, and other mutations).

amyloidosis and ELE did not differ significantly between genotype groups.

Intraclass correlation analysis for the primary outcome (DCP whole vessel density) demonstrated moderate inter-eye similarity (ICC = 0.41), supporting the use of mixed-effects modeling. The random intercept variance component was 0.82. Model fit indices for the primary model (AIC = 1124; BIC = 1168) indicated adequate fit. Comparable effect estimates were obtained using generalized estimating equations (GEE), confirming robustness of the findings.

In age- and sex-adjusted mixed-effects models (Table 4), age was independently associated with lower DCP vessel density (β = −0.10, 95% CI −0.16 to −0.03, $p = 0.006$). M694V carriage independently predicted reduced parafoveal and perifoveal DCP vessel density, while amyloidosis showed the strongest association with reduced parafoveal DCP density. Neither arthritis nor serositis significantly influenced DCP densities. SCP parameters demonstrated modest but non-significant associations.

Choroidal and outer retinal analyses (Table 5) showed age as a strong predictor of reduced choriocapillaris flow (β = −0.02, 95% CI −0.03 to −0.01, $p = 0.001$). Male sex correlated with higher CC flow (β = +0.36, 95% CI 0.04 to 0.67, $p = 0.030$). Amyloidosis and arthritis showed trends toward lower CC flow, though not statistically significant.

Optic disc parameters (Table 6) revealed no significant associations between vessel density or cup-to-disc ratio and any genetic or clinical variables. (all $p > 0.05$). Sensitivity analyses excluding eyes with SSI < 50 ($n = 7$) did not materially alter the regression results. Marginal R^2 for the primary model was 0.18, and conditional R^2 was 0.46, indicating that fixed effects explained a meaningful proportion of variance, while subject-level random effects contributed substantially to overall variability. All variance inflation factors (VIF) were below 1.8, indicating no evidence of multicollinearity among predictors.Residual diagnostics demonstrated no significant deviation from normality or homoscedasticity, and inspection of standardized residuals did not identify influential outliers.

4. Discussion

In this study, we comprehensively evaluated retinal and choroidal microvascular parameters in a large cohort of FMF patients using OCTA and compared the findings with an age- and sex-matched healthy control group. Compared with controls, FMF patients demonstrated significantly reduced DCP vessel density, particularly in the parafoveal and perifoveal regions, whereas SCP, FAZ, RNFL, and optic nerve head parameters remained largely preserved. Within the FMF cohort, age emerged as the strongest predictor of DCP and choriocapillaris decline, while M694V carriage and amyloidosis were independently associated with regional DCP reduction. Collectively, these findings suggest selective vulnerability of the DCP in FMF and support its potential role as a sensitive indicator of systemic microvascular involvement.

Our results align with evolving concepts of FMF pathophysiology. Lancieri et al. (10) described FMF as a spectrum disease shaped by genotype—phenotype interactions and vascular dysfunction. The pathogenic role of M694V, especially with amyloidosis, is well established, whereas lower-penetrance alleles such as R202Q show variable activity. In this context, DCP loss in M694V carriers and amyloidosis patients may represent systemic endothelial vulnerability, supporting the view that the eye provides a noninvasive "window" into systemic inflammation.

Large Turkish cohorts show that FMF often coexists with spondyloarthritis, vasculitis, psoriasis, or inflammatory bowel disease, affecting about one in five patients (2). By demonstrating ocular microvascular changes linked to genotype and phenotype, our results support FMF as a systemic pro-inflammatory state with multi-organ involvement. The eye may therefore serve as

Table 4. Multivariate linear regression analysis of predictors of retinal microvascular and structural parameters in FMF patients.

Outcome	Predictor	β coefficient	95% CI	*p*-value
DCP whole	Age (years)	−0.10	−0.16, −0.03	0.006**
	Male sex	+0.05	−2.01, +2.11	0.962
	M694V+	−0.62	−2.73, +1.49	0.559
	Amyloidosis	−1.63	−4.95, +1.69	0.332
	Arthritis	+0.40	−2.09, +2.90	0.748
	Serositis	+1.04	−2.98, +5.05	0.609
	ELE	+0.90	−1.50, +3.30	0.459
SCP whole	Age (years)	−0.09	−0.12, −0.05	<0.001**
	Male sex	+0.59	−0.51, +1.70	0.287
	M694V+	−0.31	−1.44, +0.82	0.590
	Amyloidosis	−0.98	−2.76, +0.80	0.277
	Arthritis	+0.05	−1.29, +1.38	0.945
	Serositis	−1.82	−3.98, +0.33	0.095
	ELE	+0.54	−0.75, +1.82	0.410
FAZ area	Age (years)	−0.00	−0.00, +0.00	0.751
	Male sex	−0.08	−0.13, −0.03	0.004**
	M694V+	−0.02	−0.07, +0.04	0.530
	Amyloidosis	−0.03	−0.11, +0.06	0.515
	Arthritis	+0.04	−0.02, +0.11	0.170
	Serositis	−0.02	−0.12, +0.08	0.733
	ELE	−0.02	−0.08, +0.03	0.409
RNFL whole	Age (years)	−0.22	−0.38, −0.06	0.007**
	Male sex	−2.16	−6.94, +2.63	0.372
	M694V+	+1.23	−3.65, +6.10	0.618
	Amyloidosis	−4.42	−12.04, +3.20	0.251
	Arthritis	−1.47	−7.26, +4.33	0.616
	Serositis	+1.71	−7.51, +10.93	0.713
	ELE	+1.61	−3.90, +7.12	0.562

β coefficient = standardized regression coefficient; CI = confidence interval; DCP = deep capillary plexus; SCP = superficial capillary plexus; FAZ = foveal avascular zone; RNFL = retinal nerve fiber layer; ELE = erysipelas-like erythema.
*$p < 0.05$, **$p < 0.01$.

Table 5. Multivariate regression analysis of choroidal and outer retinal flow parameters in FMF patients.

Outcome	Predictor	β coefficient	95% CI	*p*-value
Choriocapillaris Flow Area	Age (years)	−0.02	−0.03, −0.01	0.001**
	Male sex	+0.36	+0.04, +0.67	0.030*
	M694V+	−0.15	−0.47, +0.18	0.369
	Amyloidosis	−0.49	−1.01, +0.02	0.060
	Arthritis	+0.35	−0.04, +0.74	0.076
	Serositis	+0.42	−0.20, +1.04	0.185
	ELE	−0.25	−0.62, +0.13	0.192
Outer Retina Flow Area	Age (years)	+0.01	−0.03, +0.05	0.571
	Male sex	+0.50	−0.81, +1.80	0.451
	M694V+	−0.09	−1.43, +1.24	0.889
	Amyloidosis	+0.70	−1.40, +2.80	0.511
	Arthritis	+0.48	−1.10, +2.06	0.546
	Serositis	−0.42	−2.96, +2.12	0.744
	ELE	+0.42	−1.10, +1.94	0.585

β coefficient = standardized regression coefficient; CI = confidence interval; ELE = erysipelas-like erythema. *$p < 0.05$, **$p < 0.01$.

a sensitive and noninvasive biomarker, complementing musculoskeletal, renal, and gastrointestinal assessments.

Amyloidosis is the most severe long-term complication of FMF, driven by chronic low-grade inflammation. Varan et al. (11) showed persistent inflammation predicts amyloidosis even in remission, while the 2025 EULAR/PReS review confirmed colchicine as the cornerstone of prevention, with IL-1 blockade recommended in high-risk M694V homozygotes (12). In our study, amyloidosis (7.7%) clustered in M694V homozygotes and was linked to parafoveal DCP loss, suggesting a microvascular correlate of systemic amyloid burden. This aligns with Sahin et al. (13) who associated FMF amyloidosis with endothelial dysfunction and increased cardiovascular risk. Together, these findings suggest amyloidosis reflects systemic vascular damage, with ocular imaging offering complementary surveillance alongside renal and cardiac monitoring.

Arthritis is among the most common FMF features, affecting up to 40% of patients with variable presentation (14). Jarjour and Dodaki (15) showed M694V is the mutation most strongly associated with arthritis, while Yenigun et al. (14) noted its early onset, recurrence, and overlap with seronegative spondyloarthritis. In our cohort, arthritis was observed in nearly half of patients (47.7%) and showed a significant association with M694V carriage, reinforcing its role as a genotype-driven manifestation. However, arthritis did not independently influence OCTA-derived retinal microvascular parameters, suggesting

Table 6. Multivariate regression analysis of optic disc microvascular and structural parameters in FMF patients.

Outcome	Predictor	β coefficient	95% CI	p-value
Whole Disc Vessel Density	Age (years)	−0.00	−0.03, +0.02	0.731
	Male sex	+0.51	−0.34, +1.37	0.235
	M694V+	+0.25	−0.62, +1.12	0.562
	Amyloidosis	+0.88	−0.48, +2.24	0.203
	Arthritis	+0.58	−0.45, +1.62	0.266
	Serositis	+0.54	−1.11, +2.19	0.516
	ELE	+0.25	−0.74, +1.23	0.618
Inside-Disc Vessel Density	Age (years)	−0.07	−0.14, −0.01	0.029*
	Male sex	−0.86	−2.83, +1.11	0.390
	M694V+	+0.43	−1.57, +2.44	0.668
	Amyloidosis	−0.78	−3.92, +2.36	0.622
	Arthritis	+0.73	−1.66, +3.11	0.546
	Serositis	−0.67	−4.47, +3.13	0.726
	ELE	+0.27	−2.00, +2.54	0.812
Peripapillary Vessel Density	Age (years)	+0.02	−0.02, +0.06	0.419
	Male sex	+0.54	−0.65, +1.74	0.369
	M694V+	+0.39	−0.83, +1.60	0.531
	Amyloidosis	+1.06	−0.84, +2.97	0.269
	Arthritis	+0.35	−1.10, +1.80	0.629
	Serositis	+2.07	−0.24, +4.37	0.078
	ELE	+0.21	−1.17, +1.59	0.762
Cup-to-Disc Ratio	Age (years)	+0.00	−0.00, +0.00	0.417
	Male sex	−0.04	−0.11, +0.03	0.267
	M694V+	−0.02	−0.09, +0.05	0.620
	Amyloidosis	+0.01	−0.11, +0.12	0.887
	Arthritis	−0.02	−0.10, +0.06	0.580
	Serositis	−0.02	−0.15, +0.10	0.719
	ELE	+0.07	−0.01, +0.15	0.088

β coefficient = standardized regression coefficient; CI = confidence interval; ELE = erysipelas-like erythema.
$p < 0.05$.

that while it reflects systemic inflammatory activity, its ocular vascular impact may be less pronounced than that of amyloidosis or age-related factors. These results highlight arthritis as a clinically relevant but primarily systemic marker for risk stratification in FMF.

Serositis is a hallmark of FMF. Ben-Chetrit and Touitou (16) noted that MEFV variants influence its frequency and severity, with M694V homozygosity associated with earlier and more severe episodes, while low-penetrance alleles may remain silent. In our study, serositis frequency varied by genotype but showed no independent association with DCP density, underscoring the need for longitudinal studies.

Erysipelas-like erythema is the only pathognomonic skin sign of FMF and marks severe disease. Avar-Aydın et al. (17) reported that ELE often coincides with high-risk genotypes and systemic complications. Kolivras et al. (18) described its histology as dense neutrophilic infiltration, emphasizing endothelial activation. In our cohort, ELE did not independently predict ocular changes, but its association with M694V homozygosity mirrors systemic burden, suggesting DCP loss may represent the ocular correlate of inflammatory stress.

Previous OCTA studies in FMF cases are limited and inconsistent. Çavdarlı et al. (7) found no vascular changes in M694V carriers, while Erdem et al. (19) noted parafoveal DCP loss in a small cohort. Our larger, stratified study confirmed that M694V carriage predicts parafoveal/perifoveal DCP loss, most marked in amyloidosis patients. Differences from prior studies may reflect sample size, phenotype stratification, and regional OCTA analyses. These results support OCTA as a marker of systemic vascular health in FMF, consistent with reviews on OCTA in systemic diseases (20).

OCTA also shows value in other immune-mediated diseases. Raevis et al. (21) demonstrated its ability to detect vascular dropout in autoimmune retinopathy. Reviews in thyroid eye disease and MS show consistent macular and peripapillary vessel loss, reinforcing OCTA as a systemic and neuroinflammatory biomarker (22, 23). Notably, FMF patients show increased MS prevalence, particularly in M694V homozygotes (24). Our findings fit this broader context, suggesting OCTA may detect shared microvascular vulnerability across autoinflammatory and autoimmune diseases.

Age and sex must be considered in OCTA interpretation. Prior studies demonstrated age-related DCP decline and FAZ enlargement (25–28), with Su et al. (29) showing sex-related differences. In our cohort, DCP loss in M694V carriers and amyloidosis exceeded demographic effects, while male sex correlated with higher CC flow. This suggests FMF-related inflammation amplifies physiologic vascular changes.

In our cohort, choriocapillaris flow declined with age but was slightly higher in men. Amyloidosis and arthritis trended toward lower CC flow, while outer retina and optic disc metrics were unaffected. This differs from RA, which shows SCP loss with preserved DCP (30), and SLE, which displays macular and peripapillary deficits (31, 32). FMF thus appears to preferentially affect the DCP with sparing of optic nerve head indices. Clinically, DCP and CC may represent the most relevant OCTA endpoints in FMF.

Our findings extend the concept of FMF as a systemic vascular disease. Yin et al. (33) reaffirmed colchicine as first-line therapy, with IL-1 inhibitors for resistant cases. Yet randomized trials have not assessed microvascular outcomes or amyloidosis prevention. Our data indicate that even under colchicine therapy, subclinical vascular changes persist, underscoring OCTA's

role in monitoring FMF activity and treatment response. Because all patients were evaluated during clinical remission under stable colchicine and/or IL-1 inhibitor therapy, the observed microvascular alterations likely reflect persistent subclinical endothelial dysfunction rather than acute inflammatory activity. Although anti-inflammatory therapies may partially improve endothelial function, their specific impact on OCTA-derived retinal vessel density remains uncertain and was not directly assessed in this cross-sectional design.

This study has limitations. Its cross-sectional design precludes causal inference; inflammatory markers and treatment adherence were not uniformly available; wide-field OCTA and longitudinal follow-up were lacking; and axial length was not systematically adjusted.

Despite these limitations, strengths include being the first OCTA study to integrate both genotype and phenotype stratification in a large FMF cohort. Multivariate regional analyses identified parafoveal/perifoveal DCP alterations as sensitive biomarkers of systemic inflammatory burden, providing novel insights into the ocular vascular correlates of FMF.

5. Conclusion

In summary, FMF is associated with selective deep capillary plexus rarefaction, most pronounced in parafoveal and perifoveal regions, particularly among M694V carriers and amyloidosis patients. These findings support OCTA-derived DCP metrics as noninvasive surrogates of systemic inflammatory and endothelial dysfunction. Future longitudinal studies integrating wide-field and multimodal imaging with systemic biomarkers are needed to clarify temporal dynamics and therapeutic response. OCTA thus holds promise as a sensitive adjunct for personalized risk stratification and monitoring in FMF.

Acknowledgments

Şule Barman Kakil contributed to the conception and design of the study, data analysis and interpretation, drafting of the manuscript, and critical revision for important intellectual content. Mete Pekdiker contributed to study design, interpretation of results, and critical revision of the manuscript. Hasan Uğur Yıldız was responsible for patient recruitment, clinical data acquisition, and contributed to data organization. All authors reviewed and approved the final version of the manuscript and agree to be accountable for all aspects of the work.

Author contributions

CRediT: **Şule Barman Kakil:** Conceptualization, Data curation, Formal analysis, Funding acquisition, Investigation, Methodology, Project administration, Resources, Software, Supervision, Validation, Visualization, Writing – original draft, Writing – review & editing; **Mete Pekdiker:** Formal analysis, Investigation, Methodology, Resources, Supervision, Writing – review & editing; **Hasan Uğur Yıldız:** Data curation, Investigation, Resources, Software, Visualization, Writing – review & editing.

Disclosure statement

No potential conflict of interest was reported by the author(s).

ORCID

Şule Barman Kakil http://orcid.org/0000-0002-5750-6825
Mete Pekdiker http://orcid.org/0000-0003-3089-1564
Hasan Uğur Yıldız http://orcid.org/0009-0001-2546-0041

Data availability statement

The data underlying this article will be shared on reasonable request to the corresponding author.

References

1. Romano M, Piskin D, Kul Cinar O, Sag E. Familial Mediterranean fever; recent advances, future prospects. Diagn (Basel). 2025;15(7):813. doi:10.3390/diagnostics15070813. PMID: 40218163; PMCID: PMC11989205.
2. Tufan A, Lachmann HJ. Familial Mediterranean fever, from pathogenesis to treatment: a contemporary review. Turk J Med Sci. 2020;50(SI–2):1591–1610. doi:10.3906/sag-2008-11. PMID: 32806879; PMCID: PMC7672358.
3. Yaşar Bilge Ş, Sarı İ, Solmaz D, Şenel S, Emmungil H, Kılıç L, Yılmaz Öner S, Yıldız F, Yılmaz S, Ersözlü Bozkırlı D, et al. The distribution of MEFV mutations in Turkish FMF patients: multicenter study representing results of Anatolia. Turk J Med Sci. 2019;49(2):472–477. doi:10.3906/sag-1809-100. PMID: 30887796; PMCID: PMC7018361.
4. Baggio C, Oliviero F, Galozzi P, Guidea I, Doria A, Ramonda R, Bindoli S, Sfriso P. Unresolved issues in familial Mediterranean fever: is p.R202Q MEFV variant pathogenetic? J Clin Immunol. 2025;45(1):104. doi:10.1007/s10875-025-01898-8. PMID: 40493122; PMCID: PMC12152063.
5. Fonollosa A, Carreño E, Vitale A, Jindal AK, Ramanan AV, Pelegrín L, Santos-Zorrozua B, Gómez-Caverzaschi V, Cantarini L, Fabiani C, et al. Update on ocular manifestations of monogenic autoinflammatory diseases. Front Ophthalmol (Lausanne). 2024;4:1337329. doi:10.3389/fopht.2024.1337329. PMID: 38984133; PMCID: PMC11182141.
6. Bulut M, Kutluk O, Gedik B, Ucar U, Bozdogan YC, Sari MH, Cay HF. Evaluation of retinal and optic disc vascular structures in FMF using OCTA. Int Ophthalmol. 2023;43(7):2171–2181. doi:10.1007/s10792-022-02613-x. PMID: 36525225.
7. Çavdarli C, Çavdarli B, Topcu-Yilmaz P, Polat Gültekin B. Optical coherence tomography-angiographic vascular densities in familial Mediterranean fever (FMF) patients with M694V mutations. Ophthalmic Genet. 2020;41(3):257–262. doi:10.1080/13816810.2020.1759108. Epub 2020 May 6. PMID: 32372681.
8. Maccora I, Marrani E, Mastrolia MV, Abu-Rumeileh S, Maniscalco V, Fusco E, Barbati F, Pagnini I, Simonini G. Ocular involvement in monogenic autoinflammatory disease. Autoimmun Rev. 2021;20(11):102944. doi:10.1016/j.autrev.2021.102944. PMID: 34509650.
9. Livneh A, Langevitz P, Zemer D, Zaks N, Kees S, Lidar T, Migdal A, Padeh S, Pras M. Criteria for the diagnosis of familial Mediterranean fever. Arthritis Rheum. 1997;40(10):1879–1885. doi:10.1002/art.1780401023. PMID: 9336425.
10. Lancieri M, Bustaffa M, Palmeri S, Prigione I, Penco F, Papa R, Volpi S, Caorsi R, Gattorno M. An update on familial Mediterranean fever. Int J Mol Sci. 2023;24(11):9584. doi:10.3390/ijms24119584. PMID: 37298536; PMCID: PMC10253709.
11. Varan O, Kucuk H, Babaoglu H, Tecer D, Atas N, Bilici Salman R, Satıs H, Ozturk MA, Haznedaroglu S, Goker B, et al. Chronic inflammation in adult familial Mediterranean fever patients: underlying causes and association with amyloidosis. Scand J Rheumatol. 2019;48(4):315–319. doi:10.1080/03009742.2018.1558282.
12. Sag E, Otón T, Carmona L, Ozen S. Efficacy and safety of treatments in familial Mediterranean fever and its complications: a systematic review informing the EULAR/PReS recommendations for familial

Mediterranean fever. Ann Rheum Dis. 2025;S0003-4967(25):01034–9. doi:10.1016/j.ard.2025.05.020. Epub ahead of print. PMID: 40562663.
13. Sahin S, Romano M, Guzel F, Piskin D, Poddighe D, Sezer S, Kasapcopur O, Appleton CT, Yilmaz I, Demirkaya E. Assessment of surrogate markers for cardiovascular disease in familial Mediterranean fever-related amyloidosis patients homozygous for M694V mutation in MEFV gene. Life (Basel). 2022;12(5):631. doi:10.3390/life12050631. PMID: 35629299; PMCID: PMC9146909.
14. Yenigun S, Ayla AY, Yuzbasioglu MB, Baspinar SN, Ergun S, Karabicek A, Belli C, Demirkol F, Ozdogan H, Ugurlu S. Characteristics of arthritis in patients with familial Mediterranean fever. Intern Med J. 2024;54(11):1802–1808. doi:10.1111/imj.16495. Epub 2024 Aug 21. PMID: 39166838.
15. Jarjour RA, Dodaki R. Arthritis patterns in familial Mediterranean fever patients and association with M694V mutation. Mol Biol Rep. 2011;38(3):2033–2036. doi:10.1007/s11033-010-0326-5. Epub 2010 Sep 16. PMID: 20845072.
16. Ben-Chetrit E, Touitou I. The significance of carrying MEFV variants in symptomatic and asymptomatic individuals. Clin Genet. 2024;106(3):217–223. doi:10.1111/cge.14566. Epub 2024 May 31. PMID: 38818540.
17. Avar-Aydın PÖ, Ozcakar ZB, Aydın F, Karakaş HD, Çakar N, Yalçınkaya F. Erysipelas-like erythema: a manifestation of severe disease phenotype in pediatric patients with familial Mediterranean fever. Turk Arch Pediatr. 2022;57(6):599–602. doi:10.5152/TurkArchPediatr.2022.22058. PMID: 35950745; PMCID: PMC9682821.
18. Kolivras A, Provost P, Thompson CT. Erysipelas-like erythema of familial Mediterranean fever syndrome: a case report with emphasis on histopathologic diagnostic clues. J Cutan Pathol. 2013;40(6):585–590. doi:10.1111/cup.12132. Epub 2013 Mar 23. PMID: 23521609.
19. Erdem S, Karahan M, Ava S, Dursun ME, Cevik FC, Özkul E, Keklikci U, Çevik R. Retinal microvascular changes in patients with familial Mediterranean fever: a study based on optical coherence tomography angiography. Arq Bras Oftalmol. 2021;85(4):382–388. doi:10.5935/0004-2749.20220038. PMID: 34586239; PMCID: PMC11878385.
20. Chua J, Tan B, Wong D, Garhöfer G, Liew XW, Popa-Cherecheanu A, Loong Chin CW, Milea D, Li-Hsian Chen C, Schmetterer L. Optical coherence tomography angiography of the retina and choroid in systemic diseases. Prog Retin Eye Res. 2024;103:101292. doi:10.1016/j.preteyeres.2024.101292. Epub 2024 Aug 30. PMID: 39218142.
21. Raevis J, Etheridge T, Cleland S, Mititelu M. Autoimmune retinopathy: findings and limitations from optical coherence tomography angiography. Int J Retina Vitreous. 2020;6(1):64. doi:10.1186/s40942-020-00267-4. PMID: 33292781; PMCID: PMC7713440.
22. Rajabi MT, Sadeghi R, Abdol Homayuni MR, Pezeshgi S, Hosseini SS, Rajabi MB, Poshtdar S. Optical coherence tomography angiography in thyroid associated ophthalmopathy: a systematic review. BMC Ophthalmol. 2024;24(1):304. doi:10.1186/s12886-024-03569-5. PMID: 39039451; PMCID: PMC11265183.
23. Mohammadi S, Gouravani M, Salehi MA, Arevalo JF, Galetta SL, Harandi H, Frohman EM, Frohman TC, Saidha S, Sattarnezhad N, et al. Optical coherence tomography angiography measurements in multiple sclerosis: a systematic review and meta-analysis. J Neuroinflammation. 2023;20(1):85. doi:10.1186/s12974-023-02763-4. PMID: 36973708; PMCID: PMC10041805.
24. Yahalom G, Kivity S, Lidar M, Vaknin-Dembinsky A, Karussis D, Flechter S, Ben-Chetrit E, Livneh A. Familial Mediterranean fever (FMF) and multiple sclerosis: an association study in one of the world's largest FMF cohorts. Eur J Neurol. 2011;18(9):1146–1150. doi:10.1111/j.1468-1331.2011.03356.x. Epub 2011 Feb 8. PMID: 21299735.
25. Lavia C, Bonnin S, Maule M, Erginay A, Tadayoni R, Gaudric A. Vessel density of superficial, intermediate, and deep capillary plexuses using optical coherence tomography angiography. Retina. 2019;39(2):247–258. doi:10.1097/IAE.0000000000002413. PMID: 30550527; PMCID: PMC6358199.
26. Abay RN, Akdeniz GŞ, Katipoğlu Z, Kerimoğlu H. Normative data assessment of age-related changes in macular and optic nerve head vessel density using optical coherence tomography angiography. Photodiagn Photodyn Ther. 2022;37:102624. doi:10.1016/j.pdpdt.2021.102624. Epub 2021 Nov 12. PMID: 34775064.
27. Gómez-Ulla F, Cutrin P, Santos P, Fernandez M, Abraldes M, Abalo-Lojo JM, Gonzalez F. Age and gender influence on foveal avascular zone in healthy eyes. Exp Eye Res. 2019;189:107856. doi:10.1016/j.exer.2019.107856. Epub 2019 Oct 22. PMID: 31654619.
28. Zhou L, Wang F, Wang L, Shen P, Cao Y, He Y, Yan S, Kong X, Lu X. Quantitative assessment and determinants of foveal avascular zone in healthy volunteers. J Int Med Res. 2021;49(5):3000605211014994. doi:10.1177/03000605211014994. PMID: 33990149; PMCID: PMC8127766.
29. Su B, Zhu X, Yang K, Xiao Y, Li C, Shi K, Qu J, Lu F, Li M, Cui L. Age- and sex-related differences in the retinal capillary plexus in healthy Chinese adults. Eye Vis (Lond). 2022;9(1):38. doi:10.1186/s40662-022-00307-0. PMID: 36180939; PMCID: PMC9526290.
30. Iacono P, Da Pozzo S, Bedendo A, Arrigo A, Parravano M, Varano M, Battaglia Parodi M. Oct retinal angiography features in patients with rheumatoid arthritis: a pilot study. Eur J Ophthalmol. 2022;32(4):2433–2439. doi:10.1177/11206721211035626. Epub 2021 Jul 27. PMID: 34313159.
31. Meng L, Chen L, Zhang C, Chen H, Yang J, Wang Y, Zhang W, Cheng S, Zhao Q, Zhao X, et al. Quantitative assessment of retinal vasculature changes in systemic lupus erythematosus using wide-field OCTA and the correlation with disease activity. Front Immunol. 2024;15:1340224. doi:10.3389/fimmu.2024.1340224. PMID: 38348025; PMCID: PMC10859513.
32. Drakopoulos M, Sikora HF, Fahey JD, Mirza RG. Ophthalmic posterior segment OCTA metrics as potential biomarkers for systemic involvement in systemic sclerosis, systemic lupus erythematosus, and Behçet disease: a systematic review. Open Access Rheumatol. 2025;17:87–100. doi:10.2147/OARRR.S511810. PMID: 40313721; PMCID: PMC12044345.
33. Yin X, Tian F, Wu B, Xu T. Interventions for reducing inflammation in familial Mediterranean fever. Cochrane Database Syst Rev. 2022;3(3):CD010893. doi:10.1002/14651858.CD010893.pub4. PMID: 35349164; PMCID: PMC8962959.