Turkish Journal of Veterinary & Animal Sciences

Volume 37 | Number 6 Article 9

1-1-2013

Light and scanning electron microscopic studies on the lingual papillae of 80-day-old wild pig fetal siblings

SEVİNÇ ATEŞ

YEŞİM AKAYDIN BOZKURT

TOLUNAY KOZLU

AYDIN ALAN

AYHAN DÜZLER

Follow this and additional works at: https://journals.tubitak.gov.tr/veterinary

 Part of the Animal Sciences Commons, and the Veterinary Medicine Commons

Recommended Citation

ATEŞ, SEVİNÇ; BOZKURT, YEŞİM AKAYDIN; KOZLU, TOLUNAY; ALAN, AYDIN; and DÜZLER, AYHAN (2013) "Light and scanning electron microscopic studies on the lingual papillae of 80-day-old wild pig fetal siblings," *Turkish Journal of Veterinary & Animal Sciences*: Vol. 37: No. 6, Article 9. https://doi.org/10.3906/vet-1210-5

Available at: https://journals.tubitak.gov.tr/veterinary/vol37/iss6/9

This Article is brought to you for free and open access by TÜBİTAK Academic Journals. It has been accepted for inclusion in Turkish Journal of Veterinary & Animal Sciences by an authorized editor of TÜBİTAK Academic Journals. For more information, please contact academic.publications@tubitak.gov.tr.

TÜBİTAK

Turkish Journal of Veterinary and Animal Sciences

http://journals.tubitak.gov.tr/veterinary/

Research Article

Turk J Vet Anim Sci
(2013) 37: 664-671
© TÜBİTAK
doi:10.3906/vet-1210-5

Light and scanning electron microscopic studies on the lingual papillae of 80-day-old wild pig fetal siblings

Sevinç ATEŞ[1,*], Yeşim AKAYDIN BOZKURT[2], Tolunay KOZLU[2], Aydın ALAN[3], Ayhan DÜZLER[3]

[1]Department of Anatomy, Faculty of Veterinary Medicine, Mustafa Kemal University, Hatay, Turkey

[2]Department of Histology and Embryology, Faculty of Veterinary Medicine, Mustafa Kemal University, Hatay, Turkey

[3]Department of Anatomy, Faculty of Veterinary Medicine, Erciyes University, Kayseri, Turkey

Received: 03.10.2012 • **Accepted:** 04.02.2013 • **Published Online:** 13.11.2013 • **Printed:** 06.12.2013

Abstract: This study examined the lingual papillae of 80-day-old wild pig fetal siblings through macroscopic and light and scanning electron microscopic observations. The results revealed that fungiform papillae were located on every aspect of the tongue except the ventral surface and the center of the dorsal surface. Conical papillae were present on the dorsal surface of the root of the tongue and marginal papillae were observed on the lateral edges of the tip of the tongue. There were 2 vallate papillae on the dorsal and 2 foliate papillae on the lateral aspects of the root of the tongue. The filiform papillae normally seen in the mature stage were not observed at this stage. Taste buds were identified in all the gustatory papillae examined. On the other hand, taste pores were perceived only in the fungiform papillae. The findings acquired will surely contribute to the literature as an essential base for further related research.

Key words: Light microscopy, SEM, lingual papillae, wild pig fetus

1. Introduction

The tongue in mammals possesses 3 sections: root, body, and tip; it has 2 surfaces, dorsal and ventral, and 2 lateral margins that separate the dorsal and the ventral surfaces and meet rostrally in the formation of the tip of the tongue. There are mechanic and gustatory papillae on the dorsal surface of the tongue. The mechanic papillae (lenticular, filiform, and conical) help with the chewing and swallowing of foods while the gustatory papillae (vallate, fungiform, and foliate) receive the taste of foods.

The literature has reported on all the types of lingual papillae in mature pigs except the lenticular papilla (1–3). Moreover, the marginal papillae normally seen on the lateral edges of the tip of the tongue in the fetal and perinatal periods of human, cat, dog, pig, dolphin, and certain whale species, have been documented to disappear in the postnatal period (4–7). Even though light and scanning electron microscopic (SEM) observations have been documented on the lingual papillae of the mature domestic pig, domestic pig fetus, and mature wild pig (2,3,8), knowledge of the development of the lingual papillae in the wild pig fetus is limited. Therefore, this study focused on investigating peculiarities of the lingual papillae in the approximately 80-day-old fetal siblings of a wild pig using light and scanning electron microscopy techniques. Results of the study may be valuable in terms of identifying structural differences in the morphology of the lingual papillae between domestic and wild pigs, whose feeding and environmental conditions differ greatly. Furthermore, findings of the study, which is to our knowledge the first attempt to examine the morphology of the lingual papillae of the wild pig fetus, will surely contribute to the literature and future related research.

The literature has documented that the development of the tongue is almost completed in the early stages of gestation, before the end of the embryonic term (9). By using the tongues of 80-day-old fetuses, which have completed organogenesis, we can compare the fetal data with data from mature animals.

2. Materials and methods

The tongues of 8 fetal siblings of a wild pig hunted by villagers were used in the study. Their ages were determined to be approximately 80 days, using crown–rump length measurements (Table), as suggested by the studies by Henry (10), and Evans and Sack (11). The tongues were also macroscopically photographed (Canon Powershot, Olympus SZ).

For histological examination, the tissue samples were fixed in 10% neutral buffered formalin for 24 h.

* Correspondence: sevincates@yahoo.com

Table. Crown–rump length measurements.

Age (days)	Domestic pig fetus length (mm) (10,11)		European wild pig fetus length (mm) (10)		Wild pig fetus length (mm) in the study	
	Average	Range	Average	Range	Average	Range
80	176 (10) 200 (11)	137–189 (10)	185.1	180–190	185.6	160–210

Following routine histological procedures, the tissue samples were embedded in paraffin and sectioned into 5-µm thicknesses. Subsequently, a modified Mallory's triple staining technique (12) was applied to observe the general histologic structures of the tongues. The sections were examined under a light microscope (Olympus BX50, Japan).

For scanning electron microscopic observation, samples with a volume of 0.5 cm^3 were taken from 4 fetuses and fixed with 2.5% gluteraldehyde for 48 h. They were then immersed in phosphate buffered saline for 10 min, in 1% OsO_4 for 1 h, and in an acetone series. After critical point drying with CO_2, the samples were finally covered with gold–palladium, and observed with a scanning electron microscope (Leica LEO 440) (13,14).

Nomina Anatomica Veterinaria (15) was applied for anatomical nomenclature.

3. Results

At gross observation (Figure 1), the tongues were dorsally cylindrical in shape, laterally thick and well-rounded at the root and body, and thinner at the tip. The lengths of the tongues were 43–45 mm, and the widths were 14–16 mm. There were 2 vallate papillae symmetrically located on the dorsal surface of the root of the tongue, and 2 foliate papillae placed in front of the palatoglossal arch on the lateral edge of the root of the tongue. The conical papillae were seen between the vallate papillae and the base of the epiglottis. The fungiform papillae were present on almost every aspect of the tongue except the ventral surface and the center of the dorsal surface. However, the marginal papillae were observed throughout the lateral edges of the tip of the tongue. None of the examined tongues possessed filiform papillae at the macroscopic level.

3.1. Papillae on the root of the tongue

3.1.1. Conical papillae

There were numerous conical papillae (Figure 2) with their blunt or sharp tips directed caudally, of 200–750 µm in length, observed on the root of the tongue. They comprised mostly round secondary tubercles located near their bases while some possessed double apices. The papillae were covered by the stratified squamous epithelium. There were undeveloped mix salivary glands located in the lamina propria layer on the base of the tongue.

3.1.2. Vallate papillae

The oval papillae (Figure 3) were obliquely located longitudinally, forming a prominent angle on the root of the tongue. There were eminent tubercles and grooves on the dorsal surface of the papillae. The vallate papillae were separated from the surrounding tissue by a vallum of approximately 40 µm in width. Each papilla was encircled by an annular pad. The heights of the papillae were approximately 200 µm, and that of the vallum was nearly 60 µm.

The vallate papillae contained stratified squamous epithelium, with taste buds on the dorsal surface of the papilla and on the interior surface of the vallum. The taste buds were still at a premature stage, possessing no taste pores yet. There were also premature Ebner glands (gl. gustatoria), located submucosally beneath the vallum, comprising excretory ducts.

3.1.3. Foliate papillae

The foliate papillae (Figure 4) were formed of 3–5 leaves with grooves in between. The surfaces of the papillae were

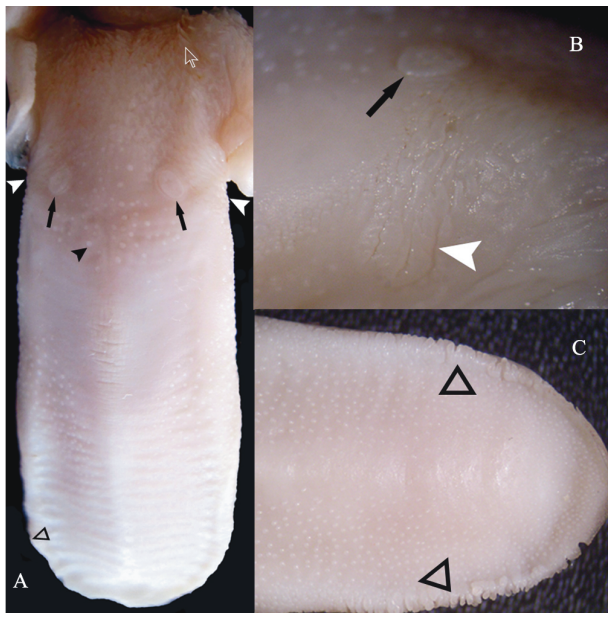

Figure 1. (A, B, C). Macroscopic view of the tongue and lingual papillae. White arrowhead = the foliate papillae, black arrows = the vallate papillae, black arrowhead = the fungiform papilla, transparent arrow = the conical papilla, and black triangles = the marginal papillae.



Figure 2. Scanning electron (A) and light microscopic (B) views of the conical papillae. White asterisk = the papilla with double apices, white arrowhead = round secondary tubercle, black arrowhead = the papilla with a sharp tip, and black arrow = the papilla with a blunt tip.

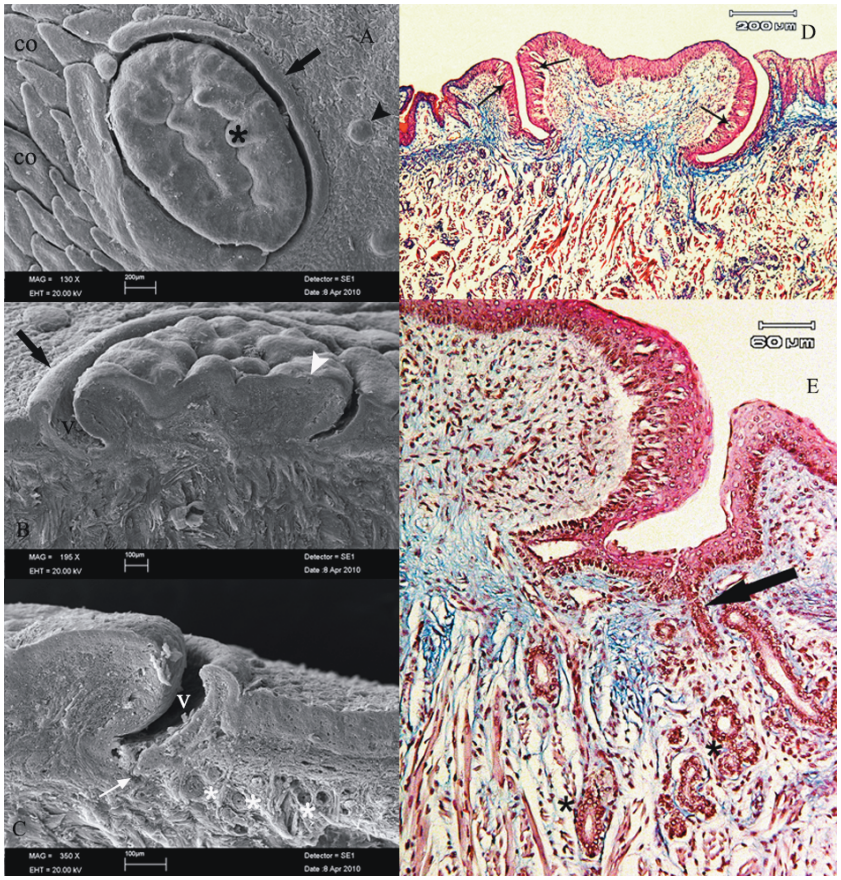

Figure 3. Scanning electron (A, B, C) and light microscopic (D, E) views of the vallate papillae. A) co = the conical papillae, asterisk = an eminent tubercle on the dorsal surface of the papilla, black arrow = annular pad, and black arrowhead = the fungiform papilla. B) v = vallum, black arrow = annular pad, and white arrowhead = taste bud. C) v = vallum, white asterisk = Ebner (gustatoric) glands, and white arrow = excretory duct. D) Black arrows = taste buds. E) Black asterisk = Ebner (gustatoric) glands and black arrow = excretory ducts.

not smooth, occasionally displaying irregular tuberous areas. Taste buds were seen on the surfaces of the leaves that face each other, but not yet containing any taste pores reaching the epithelial surface. The taste buds in the non-keratinized stratified squamous epithelium were determined not to be fully developed yet. Excretory ducts and mucous (Ebner) gustatoric glands were seen in the lamina propria.



Figure 4. Scanning electron (A) and light microscopic (B) views of the foliate papillae. A) White asterisk = leaves and g = groove. B) Black asterisk = Ebner (gustatoric) gland and black arrowheads = taste buds.

3.2. Papillae on both the body and the tip of the tongue

3.2.1. Fungiform papillae

The fungiform papillae (Figure 5) were located on every aspect of the tongue except the ventral surface and the center of the dorsal surface. They were either oval or round in shape and 150–220 µm in diameter. The round ones were separated from the surrounding tissue by a shallow groove of 15–20 µm in width. The diameters and heights of the papillae increased as their numbers decreased when located caudally. Light microscopic observations revealed that the papillae were covered by stratified squamous epithelium. Each of the oval fungiform papillae had one taste bud at the tip, with taste pores. Likewise, the round fungiform papillae comprised 1–4 taste buds at the developmental stage with no taste pores. The taste buds had 2 indistinct cell types characterized by either clear (gustatoric) or dark (connective) stains.

3.2.2. Filiform papillae

There were no fully developed filiform papillae observed on the tongue; however, there were some tuberous structures covered by a thin keratin layer on the dorsal surface of the caudal third of the tongue (Figure 5).

3.3. Papillae on the tip of the tongue

3.3.1. Marginal papillae

Numerous marginal papillae (Figure 6) were present in a digital shape throughout the lateral edges of the tip of the tongue. They were enclosed by the stratified squamous epithelium. There were abundant eminent microscopic

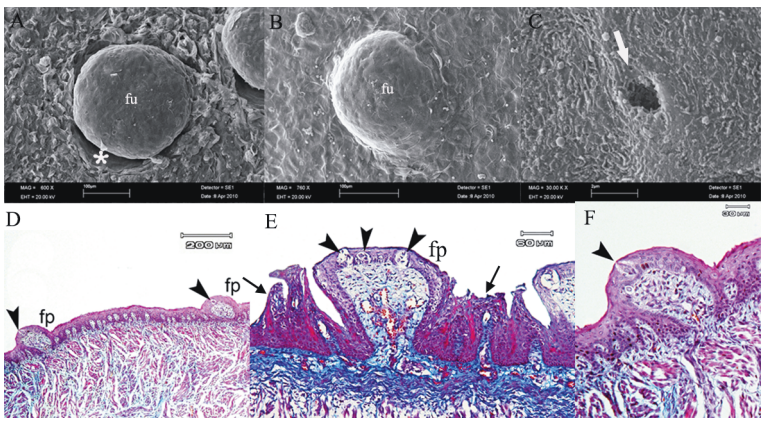

Figure 5. Scanning electron (A, B, C) and light microscopic (D, E, F) views of the fungiform papillae. A) fu = the oval fungiform papillae. B) White arrow = taste pores on the dorsal surface of the oval fungiform papilla. C) fu = the round fungiform papilla with surrounding groove and white asterisk = groove. D) fp = the oval fungiform papillae and black arrowhead = taste bud with taste pores. E) Black arrowhead = taste bud with taste pores on the dorsal surface of the oval fungiform papillae. F) fp = the round fungiform papillae with surrounding groove, black arrowheads = taste buds, black arrow = draft of the filiform papillae, and black asterisk = groove.

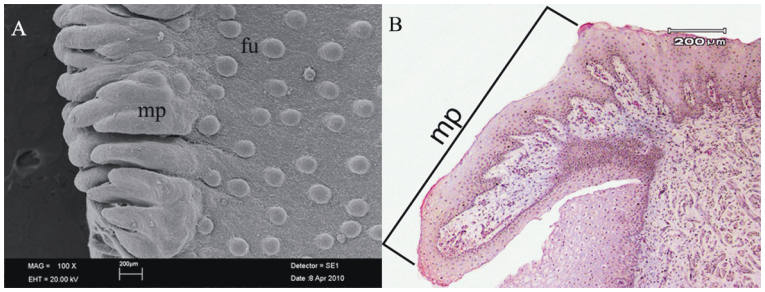

Figure 6. Scanning electron (A) and light microscopic (B) views of the marginal papillae. mp = the marginal papillae and fu = the fungiform papillae.

papillae in the lamina propria, projecting into the epithelial lamina.

Scanning electron microscopic observations at higher magnifications (Figure 7) showed that the papillae had a surface that comprised polygonal cells with thicker edges and microridges. The microridges were only fibrous in shape on all papillae except the conical papillae, which had both fibrous and pinpoint-shaped microridges.

4. Discussion

Several studies done on both animals and humans have revealed structural and functional peculiarities of the lingual papillae at the mature stage (5,7,16). These have also been observed in the fetal and postnatal periods of humans and animals, indicating the presence of the marginal papillae, which usually disappear later on. Furthermore, the lingual papillae of the mature domestic pig, domestic pig fetus, and mature wild pig (2,3,8,17) have been documented via light and scanning electron microscopic observations. Likewise, this study investigated the morphological characteristics of the lingual papillae in wild pig fetuses using light and scanning electron microscopy techniques. Thus, the findings acquired were compared to research conducted previously on the papillae of the tongue in domestic pig fetuses.

Conical papillae, generally found in the Ruminantia (18,19), have also been seen on the tip of the tongue of 76-day-old pig fetuses as papilla draft (17) and have been reported on the root of the tongue, directing caudally, in mature pigs (2). This literature has documented 2 types of conical papillae, one with wider base and a sharp point and the other with a blunt point. Our results were different from the findings of Tichy (17) but similar to those of Kumar and Bate (2); there were abundant conical papillae on the base of the tongue, pointed caudally through the pharynx. They were typically conical, possessing sharp or blunt tips and small round tubercles located near their bases. Some of the conical papillae had double apices.

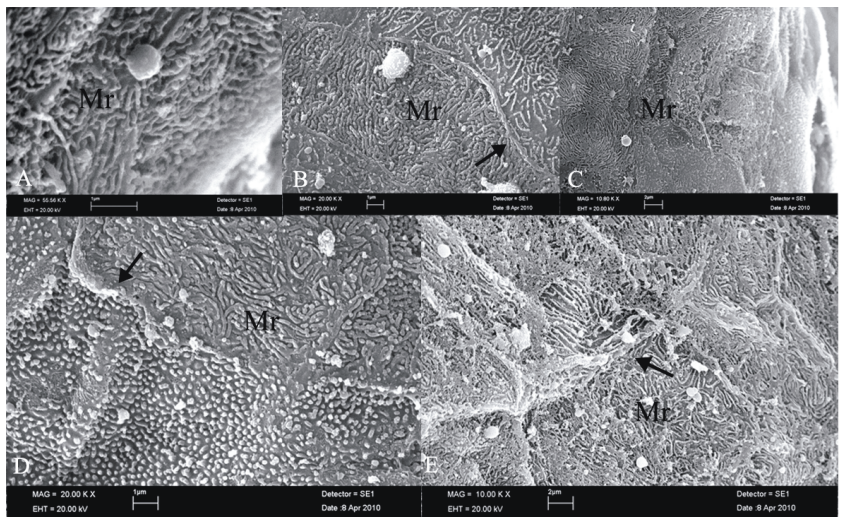

Figure 7. Scanning electron microscopic views of the surfaces of the lingual papillae at higher magnifications. A) The conical papilla. B) The vallate papilla. C) The foliate papilla. D) The fungiform papilla. E) The marginal papilla. Mr = microridges and black arrow = the thickness of the polygonal cell margins.

Mixed salivary glands in an undeveloped stage were observed in the lamina propria of the radix of the tongue, which is supported by the literature (17); however, lymph nodes documented in the lamina propria of the conical papillae in the adult domestic pig (2) were not seen in this study.

The literature has documented that the number of vallate papillae differs greatly among species (8,20–24), but it has been reported to be 2 for pigs (2,3,17,25,26). One study indicated the presence of drafts of these papillae in 44-day-old pig fetuses. They resembled the shapes of the mature papillae on day 50 of pregnancy but possessed no developed vallum (3). The vallum began developing on day 53 and completed its development on day 64. The first taste buds began developing on day 50 on the dorsal surface of the vallate papillae and, particularly after day 64, expanded through the lateral wall of the papillae and vallum. After this stage, a few taste buds were observed on the dorsal surface of the papillae. Another report (17) indicated that the tips of the taste buds reached the epithelial surface in 76-day-old fetuses, and after day 81, taste pores developed on rare occasions. Thus, light and dark cells of the taste buds, which began differentiating after day 53 of fetal age, became evident on day 76. They were regularly observed on the taste pores after day 94.

The literature has reported tubercles and indentations at various lengths along the dorsal surface of the vallate papillae (2,3,17,26). Thin tubular secondary ducts that open out from the base of the indentations were first observed on fetal day 64 and they have been documented to disappear in mature pigs (3,17). In our study, there were 2 vallate papillae in the 80-day-old fetuses. They were fully developed, comprising tubercles and indentations with no secondary ducts. Taste buds with undeveloped cells were also evident, mostly on the lateral and occasionally on the dorsal surface of the papillae, but no taste pores had developed yet. The results obtained were in parallel with the findings of the literature (17), which documented the peculiarities of the vallate papillae in nearly 80-day-old domestic pig fetuses.

The foliate papillae have been reported to first begin developing on day 57 of gestation in pig fetuses (17). The foliate papillae present in humans and various animals (2,22) have been documented to be composed of 4–5 leaves with deep grooves between them on the lateral edges of the root of the tongue (2,22,27). Those studies also indicated the presence of pseudopapillae of various shapes and sizes on the free edges of the leaves. Their taste pores have been reported to be in the grooves and not on the surface (2). Likewise, the results of our study on the morphology of the foliate papillae are similar to the descriptions in the literature indicated above. No taste pores were observed since development of the taste buds embedded in the non-keratinized multilayer epithelium covering the papillae had not yet been completed. On the other hand, excretory ducts of the secretory glands and mucous gustatory glands were demonstrated in the lamina propria.

Fungiform papillae were found scattered on almost every aspect of the tongue, and were either oval (2) or round (2,18,26,28). The oval papillae, which contained no taste buds, were mostly located on the dorsal aspect while the round ones were observed on the dorsolateral edges and possessed abundant taste buds (2). The number of taste buds on the dorsal aspect of the papilla was observed to be either one (1) or a few (2,25). Another paper (25) has researched the number of taste buds in pigs, reporting that the vallate papillae have many more taste buds than the fungiform papillae do. In this study, fungiform papillae were observed on almost every surface of the tongue except the center of the dorsum lingua and the ventral surface. Some of the fungiform papillae located in front of the vallate papillae and on the caudolateral edges of the tongue were separated from the surrounding tissue by a shallow groove like the one seen in lambs (18), goats (19), and 2-humped camels (21). A taste bud with taste pores was observed on the dorsal surface of the fungiform papillae that have no groove. On the other hand, the papillae with grooves had 1–4 taste buds with no developed taste pores on the dorsal surface.

A study done on pig fetuses (17) found that both the fungiform and vallate papillae begin developing roughly at the same time, and complete their morphogenesis on day 92 of gestation. Tichy (17) reported the presence of taste buds on the fungiform papillae on day 94 of gestation.

Filiform papillae have been observed on every aspect of the tongue (2,11,17,18,23). Present as 2 forms, blunt and sharp (2), they have been reported to begin developing as irregular tubercles on day 92 of gestation in pig fetuses (26). In our study, no typical filiform papilla were observed; however, in the histological observations, there were evident tubercles covered by thin keratinized layers observed on the dorsal surface of the caudal third region, which led us to think that they might be the drafts of these papillae.

This study has identified marginal papillae, which have also been seen in various other species including human, cat, dog, pig, whale, and dolphin (4,5,6,16). The results were similar to what the literature reports. They are known to play positive roles in sucking (7).

Studies (9,29) have suggested the sensory nerves have an important role in the formation of the gustatory papillae. Our study has revealed that the gustatory papillae are highly developed while the mechanical filiform papillae are not, indicating there is an earlier development of the gustatory papillae than the mechanical ones in wild pig.

Scanning electron microscopic observations at higher magnifications revealed polygonal cells with thicker edges and microridges on the lingual papillae (1,20,27,30). These

cells have also been documented on the surfaces of all the papillae examined in this study. The density and size of the microridges vary among the papillae (Figure 7), but their count seems to be highest in the mechanical papillae.

To sum up, the lingual papillae of the nearly 80-day-old wild pig fetuses have been examined using SEM and histological techniques, showing that their peculiarities are similar to the findings for domestic pig fetuses of similar ages. Except for the filiform papillae, the entire set of papillae specific to mature pigs was identified, along with the marginal papillae, which typically disappear at the mature stage. Filiform papillae, reported to begin developing at later stages (17,26), were not observed in the fetuses examined in this study.

References

1. Boshell JL, Wilborn WH, Singh BB. Surface morphology and bacterial flora of the dorsum of the pig tongue. Scanning Electron Microsc 1979; 3: 363–368.
2. Kumar S, Bate LA. Scanning electron microscopy of the tongue papillae in the pig (*Sus scrofa*). Microsc Res Technique 2004; 63: 253–258.
3. Tichy F. The morphogenesis of circumvallate papillae and the differentiation of taste buds in the pig at 41 to 64 days of prenatal development. Acta Vet Brunensis 1991; 60: 99–110.
4. Kastelein RA, Dubbeldam JL. Marginal papillae on the tongue of the Harbour porpoise *(Phocoena phocoena)*, Bottlenose dolphin *(Tursiops truncatus)* and Commerson's dolphin *(Cephalorhynchus commersonii)*. Aquatic Mamm 1990; 15: 158–170.
5. Schneider C, Kressin M, Schnorr B. Zur morphologie der zungenrandpapillen neugeborener ferkel. Anat Histol Embryol 1996; 25: 95–100.
6. Shindo J, Yamada TK, Yoshimura K, Kageyama I. Morphology of the tongue in a newborn Stejneger's beaked whale (Mesoplodon stejnegeri). Okajimas Folia Anat Japonica 2008; 84: 121–124.
7. Yamasaki. F, Takahashi K. A description of the times of appearance and regression of marginal lingual papillae in human fetuses and newborns. Anat Rec 1982; 204: 171–173.
8. Chamorro CA, Depaz P, Fernández JG, Anel L. Fungiform papillae of the pig and the wild boar analyzed by scanning electron microscopy**.** Scanning Microsc 1993; 7: 313–22.
9. Latshaw WK. Veterinary Developmental Anatomy. Ontario, Canada: B.C. Decker, 1987.
10. Henry VG. Fetal development in European wild hogs. J Wildl Manage 1968; 32: 966–970.
11. Evans HE, Sack WO. Prenatal development of domestic and laboratory mammals: growth curves, external features, and selected references. Anat Histol Embryol 1973; 2: 11–45.
12. Crossmon G. A modification of Mallory's connective tissue stain with a discussion of the principles involved. Anat Rec 1937; 69: 33–38.
13. Echlin P, Joy DC, Newbury DE. Advanced Scanning Electron Microscopy and X-ray Microanalysis. New York, USA: Plenum Press, 1986.
14. Hajibagheri MAN. Electron Microscopy Methods and Protocols. Totowa, NJ, USA: Humana Press, 1999.
15. International Committee on Veterinary Gross Anatomical Nomenclature: General Assembly of the World Association of Veterinary Anatomists. Nomina Anatomica Veterinaria. 5th ed. Hannover, Columbia (MO, USA), Ghent, Sapporo. 2005.
16. Schlechta C, Kressin M, Schnorr B, Krebs C. Architektur und feinstruktur der terminalen blutgefabe der zungenrandpapillen neugeborener ferkel. Ann Anat 1996; 178: 137–143.
17. Tichy F. The morphogenesis of circumvallate papillae and the differentiation of taste buds in the porcine foetus from day 76 till birth and in the adult pig. Acta Vet Brunensis 1991; 60: 307–315.
18. Tadjalli M, Pazhoomand R. Tongue papillae in lambs: a scanning electron microscopic study. Small Ruminant Res 2004; 54: 157–164.
19. Kumar P, Kumar S, Singh Y. Tongue papillae in goat: a scanning electron-microscopic study. Anat Histol Embryol 1998; 27: 355–357.
20. Agungpriyono S, Yamada J, Kitamura N, Nisa C, Sigit K, Yamamoto Y. Morphology of the dorsal lingual papillae in the lesser mouse deer, *Tragulus javanicus*. J Anat 1995; 187: 635–640.
21. Erdunchaolu E, Takehana K, Yamamoto E, Kobayashi A, Cao G, Aiyin B, Ueda H, Tangkawattana P. Characteristics of dorsal lingual papillae of the Bactrian camel (*Camelus bactrianus*). Anat Histol Embryol 2001; 30: 147–151.
22. Iwasaki S, Asami T. Morphological study of lingual papillae in the fetal cat at mid-gestation, as revealed by light and scanning electron microscopy. Odontology 2002; 90: 22–26.
23. Kurtul I, Atalgın ŞH. Scanning electron microscopic study on the structure of the lingual papillae of the Saanen goat. Small Ruminant Res 2008; 80: 52–56.
24. Ünsaldı E, Yılmaz S. Sincaplarda (*Sciurus vulgaris*) papilla vallata'nın makroskobik ve ışık mikroskobik yapısı. FÜ Sağ Bil Vet Derg 2009; 23: 83–88.
25. Mack A, Singh A, Gilroy C, Ireland W. Porcine lingual taste buds: a quantitative study. Anat Rec 1997; 247**:** 33–37.
26. Tichy F. The morphogenesis of selected lingual papillae in ovine and porcine fetuses observed by scanning electron microscopy. Acta Vet Brunensis 1992; 61: 3–10.
27. Toprak B, Yılmaz S. Investigations on postnatal development of the foliate papillae of the tongue by the light and scanning electron microscopy in the white laboratory mice. Revue Méd Vét 2007; 158: 479–482.

28. Tozak YH, Özdamar S. İnsan fetuslarında dil papillalarının gelişiminin taramalı electron mikroskobunda incelenmesi. Erciyes Üniversitesi Sağlık Bilimleri Dergisi 2009; 18: 129–137.

29. Whitehead MC, Kachele DL. Development of fungiform papillae, taste buds, and their innervation in the hamster. J Comp Neurol 1994; 340: 515–530.

30. Hersch M, Ganchrow D. Scanning electron microscopy of developing papillae on the tongue of human embryos and fetuses. Chem Senses 1980; 5: 331–341.