Check for updates

Received: 3 November 2021 | Accepted: 9 December 2021

DOI: 10.1111/ahe.12777

ANATOMIA HISTOLOGIA EMBRYOLOGIA JOURNAL OF VETERINARY MEDICINE WILEY

ORIGINAL ARTICLE

# Morphology of septomarginal trabeculae in Hatay mountain gazelle (Gazella gazella)

Baran Erdem[1] | Tolga Tutar[2] | Lutfi Takci[3] | Yeşim Akaydin Bozkurt[2] | Sevinç Ateş[1]

[1]Department of Anatomy, Faculty of Veterinary Medicine, Hatay Mustafa Kemal University, Hatay, Turkey

[2]Department of Histology and Embryology, Faculty of Veterinary Medicine, Hatay Mustafa Kemal University, Hatay, Turkey

[3]Faculty of Veterinary Medicine, Department of Anatomy, Sivas Cumhuriyet University, Sivas, Turkey

**Correspondence**
Baran Erdem, Department of Anatomy, Faculty of Veterinary Medicine, Hatay Mustafa Kemal University, Hatay, Turkey.
Email: s.baran.erdem@gmail.com

## Abstract

This study was conducted to reveal the anatomical and histological features of left and right septomarginal trabeculae in the heart of the Hatay mountain gazelle. In the study, two female and two male adult Hatay mountain gazelle hearts were used. For this purpose, the materials detected in 10% formaldehyde solution were stained with Crossman's modified triple staining technique and examined under a light microscope after anatomical examinations and measurements were made. The presence of trabeculae in both ventricles was demonstrated. While the number of septomarginal trabeculae was 1 in each of the samples in the right ventricle, it was determined that it was 2 in each of three hearts and 3 in one heart in the left ventricle. It was observed that the right trabeculae were unbranched and fleshy, while the left trabeculae were filamentous and mostly branched. The lengths and thicknesses of the right trabeculae were measured 12–17 mm and 3–4 mm and the lengths and thicknesses of the left trabeculae were measured 6–15 mm and 0.5–1 mm. In the histological examination of both trabeculae, connective tissue, Purkinje fibres and blood vessels were observed, in addition, it was detected that the right trabeculae had myocardial fibres. Few capillaries were found in the left trabecula, while both more capillaries and blood vessels were found in the right trabeculae.

KEYWORDS
Gazella gazelle, Hatay mountain gazelle, moderator band, septomarginal trabecula, ventricular band

## 1 | INTRODUCTION

Cardiovascular system diseases are among the most common and deadly diseases of our age. Especially rhythm disorders, vascular occlusions, or valvular insufficiency affect life very negatively. The morphology of the heart has been studied in detail in humans and various animal species. The heart, which has a conduction system, makes rhythmic contractions without being stimulated by external stimuli (Noyan, 1998; Özer, 2008). While the speed of these contractions is controlled by the autonomous system, the pulsation occurs with its conduction system. The heart's conduction system is formed by modified heart muscle cells. This system consists of sinoatrial node, atrioventricular node, His bundles, and Purkinje fibres. The impulse that occurs in the sinoatrial node reaches the atrioventricular node, from there to the His bundles and finally to the Purkinje fibres in the right and left ventricular walls and distributes in the heart muscle (Noyan, 1998; Özer, 2008; Padala et al., 2021). It has been reported that Purkinje fibres are also found in the structure of left and right septomarginal trabeculae (Ates et al., 2017; Bombonato et al., 2012; Ghonimi et al., 2014; Gulyaeva & Roshchevskaya, 2012; Sathyamoorthy & Ramesh, 2008). The trabeculae are constant structures in the right ventricle in humans and

 © 2021 Wiley-VCH GmbH 

animals while species and individual differences are observed in the left ventricle (Armiger et al., 1979; Gerlis et al., 1984; Ghonimi et al., 2014; Gulyaeva & Roshchevskaya, 2012; Haligur & Dursun, 2009; Truex & Warshaw, 1942). In various studies, it is stated that the structures containing conductive tissue may cause premature beats, arrhythmias (Barber et al., 2019; Lerman et al., 2018; Sadek et al., 2015) or innocent heart murmurs (Koie et al., 2007).

Hatay mountain gazelle is a species of gazella in the horn family, in the mammal class. Gazella gazella, which is widespread in the Arabian Peninsula, South Lebanon, Israel, and Iran in the world, is a single population in our country and is found only in a narrow area on the Turkish–Syrian borderline of Kırıkhan district. This region is the northernmost distribution area of Gazella gazella in the world. Hatay Mountain gazelle is one of the two gazelle species found in Turkey. The existence of this species, which was thought to be extinct until 2008, was determined by the studies and they took under protection. Gazelles prefer living areas in hilly mountainous areas, especially close to agricultural areas. Males and females of the Hatay Mountain gazelle, which is an ungulate species, weighs between 17–29.5 kg and 16–25 kg respectively. Both sexes have horns, but female horns are shorter and slender. Their colour is brown in harmony with nature, and the abdomen is white (Özkan, 2020).

In this study, it was aimed to reveal the characteristics of right and left septomarginal trabeculae belonging to the Hatay mountain gazelle. It was thought that the findings obtained from the research will both contribute to the literature on wild animals and be useful for experimental or clinical studies to be conducted in different disciplines related to the subject.

## 2 | MATERIAL AND METHODS

In the study, four mature (two females, two males) Hatay Mountain gazelle hearts fixed in 10% formaldehyde solution were used. The hearts used in the study were obtained from animals that died during the treatment at the Animal Hospital of Mustafa Kemal University. The hearts were cut at the level of the coronary sulcus to separate the atria from the ventricles. To examine the left and right ventricular cavities, the ventricular walls were cut along the interventricular subsinosal and paraconal groove, and the right and left ventricular cavities were entered. Septomarginal trabeculae observed in both ventricles were examined macroscopically and photographed. Additionally, tissue samples were taken from the septomarginal trabeculae of both ventricles for light microscopic examinations.

Tissue samples fixed in 10% neutral formaldehyde for light microscopic examinations were dehydrated with a graded alcohol series from 70% to 100% after 24 h of washing in tap water. After being kept in xylol, samples were embedded in paraplast and transversal sections were taken. Crossman's modified triple staining technique (Denk et al., 1989) was applied to the 5-μm serial sections taken from the prepared paraffin blocks to reveal the general structure of the tissues. Examination and photographing of tissue sections were performed with an Olympus BX50 research microscope.

## 3 | RESULTS

In all hearts examined, one septomarginal trabecula was detected extending between the anterior papillary muscle and the septal papillary muscle in the right ventricle (Figure 1). In two of the four hearts, the right septomarginal trabeculae were under the inconspicuous septal papillary muscle, between the septum and base of the anterior papillary muscle (Figure 1a). In one of the other two hearts, where the septal papillary muscles were prominent, the septomarginal trabecula extended between the body of the septal papillary muscle and base of the anterior papillary muscle (Figure 1b), and in the remaining heart, that is, between the body of the septal papillary muscle and the upper third of the anterior papillary muscle (Figure 1c).

It was determined that the moderator bands extending horizontally or slightly inclined in the ventricular cavity were cylindrical and fleshy (Figure 1). All right septomarginal trabeculae were unbranched. The lengths of these moderator bands were measured between 12 and 17 mm and the thicknesses between 3 and 4 mm. Additionally, in one of the two hearts with prominent septal papillary muscle, one tendinous chord originating from one of the moderator bands was observed to attach to the septal cusp (Figure 1c). In the other heart, three tendinous chords originating from the moderator band were detected (Figure 1b). Two of these chords were attached to the anterior cusp and one to the septal cusp. While the number of left septomarginal trabeculae was 2 (Figure 2a–c) in three of the hearts examined, it was 3 (Figure 2d) in one of the hearts. It was estimated that the septomarginal trabeculae originated from the subatrial papillary muscle, subauricular papillary muscle, or the outer wall and extended into the septum. Generally, it was shown that the ends of these septomarginal trabeculae attached to the septum were divided into branches, while the other end was found to be unbranched. Two of these trabeculae were unbranched (Figure 1a), three of them were bifurcated (Figure 1b), one of them was radial (Figure 1c) and three of them were reticulated (Figure 1d). The lengths of these septomarginal trabeculae were measured 6–15 mm. The thickness of all trabeculae was measured to be between 0.5 and 1 mm.

In light microscopic examinations, it was estimated that Purkinje cells were in a single bundle in the right septomarginal trabeculae, located in the centre of two of the four samples (Figure 3a) and at the periphery of the trabecula in the other two samples (Figure 3b,c). It was observed that the Purkinje cells in the bundle were localized in the form of small groups of double or triple adjoining, with abundant connective tissue between them. There was not any distinct connective tissue sheath surrounding the Purkinje bundle. In the left septomarginal trabecula, many bundles of Purkinje fibres located in the connective tissue were found (Figure 4). It was observed that these Purkinje bundles generally contained 7–8 cells, however, the number of cells could vary between 3 and 15, and these bundles showed a dispersed localization.

While myocardial cells surrounding the Purkinje bundle were intensely observed in the right septomarginal trabecula (Figure 3),




**FIGURE 1** (a–c) Moderator bands in the right ventricle of the Hatay Mountain gazelle hearts; cs: septal cusp, ca: anterior cusp, cp: posterior cusp, m: anterior papillary muscle, p: posterior papillary muscle, s: septal papillary muscle, arrowheads: septomarginal trabecula, arrows: tendinous chord

myocardial cells were not found in the left septomarginal trabecula (Figure 4). The left septomarginal trabecula was surrounded by a connective tissue sheath from the periphery, and the area between the Purkinje cell groups was completely composed of connective tissues. Blood vessels were found between myocardial cells in right septomarginal trabecula and capillaries were found in the connective tissue surrounding and intervening the Purkinje bundle. Left septomarginal trabecula had fewer capillaries compared with those in right septomarginal trabecula and large blood vessels were not found. While tendinous chord was not found in the left trabecula septomarginal, there were two tendinous chords (Figure 3b) in right septomarginal trabecula. Tendinous chords contained only fibrous connective tissue. In addition, no Purkinje fibres and blood vessels were found in the tendinous chord.

## 4 | DISCUSSION

Septomarginal trabeculae are reported to be filamentous structures found in the right and left ventricles of humans and animals (Ateş & Çakır, 2010; Ates et al., 2017; Bombonato et al., 2012; Ghonimi et al., 2014; Gulyaeva & Roshchevskaya, 2012; Haligur & Dursun, 2009; Kosinski et al., 2010, 2013; Perez et al., 2018; Truex & Warshaw, 1942). They are reported to be one of the fixed structures of the right ventricle (Ates et al., 2017; Bombonato et al., 2012; Cope, 2016b; Ghonimi et al., 2014; Kosinski et al., 2010, 2013). It is stated that they are not always present in the left ventricle (Ghonimi et al., 2015; Nascimento et al., 2019). For filamentous structures that do not attach to the mitral valve in the left ventricle, apart from left septomarginal trabecula, some authors have described 'left ventricular band' (Deniz et al., 2004; Gerlis et al., 1984), 'false tendons' or 'abnormal chord' (Abdulla et al., 1990; Kervancioglu et al., 2003; Loukas et al., 2007; Özbağ et al., 2002; Philip et al., 2011; Silbiger, 2013) are also used. In Nomina Anatomica Veterinaria (N.A.V.) (2017), a singular nomenclature for the right and a plural nomenclature for the left were used to express that septomarginal trabeculae may be single in the right ventricle and more than one in the left ventricle. In this study, we found it appropriate to use N.A.V (2017) as a reference for naming.

In the literature, it has been reported that the right septomarginal trabecula extends between the septum—outer wall (Evans & De Lahunta, 2013; Nascimento et al., 2019; Ravindran & Victor, 1982) septum—anterior papillary muscle (Ghonimi et al., 2015; Kosinski et al., 2010; Leao et al., 2010; Nascimento et al., 2019; Raghavendra et al., 2013), anterior papillary muscle—outer wall (Arıncı & Elhan, 2014; Ateş & Çakır, 2010; Cope, 2016b; Evans & De Lahunta, 2013), and septal papillary muscle—anterior papillary muscle (Ates et al., 2017; Gulyaeva & Roshchevskaya, 2012; Perez et al., 2018). In our study, it was determined that the right septomarginal trabecula extended between the septal papillary muscle and the anterior papillary muscle. In two hearts, the septal ends of the septomarginal trabeculae originated from the body of the prominent septal papillary muscles. In the other two hearts, it was observed that the septal ends were attached to the septum under unconscious septal papillary muscles.

The moderator band is a structure that extends from the anterior papillary muscle to the septum. It has been stated that the dog does

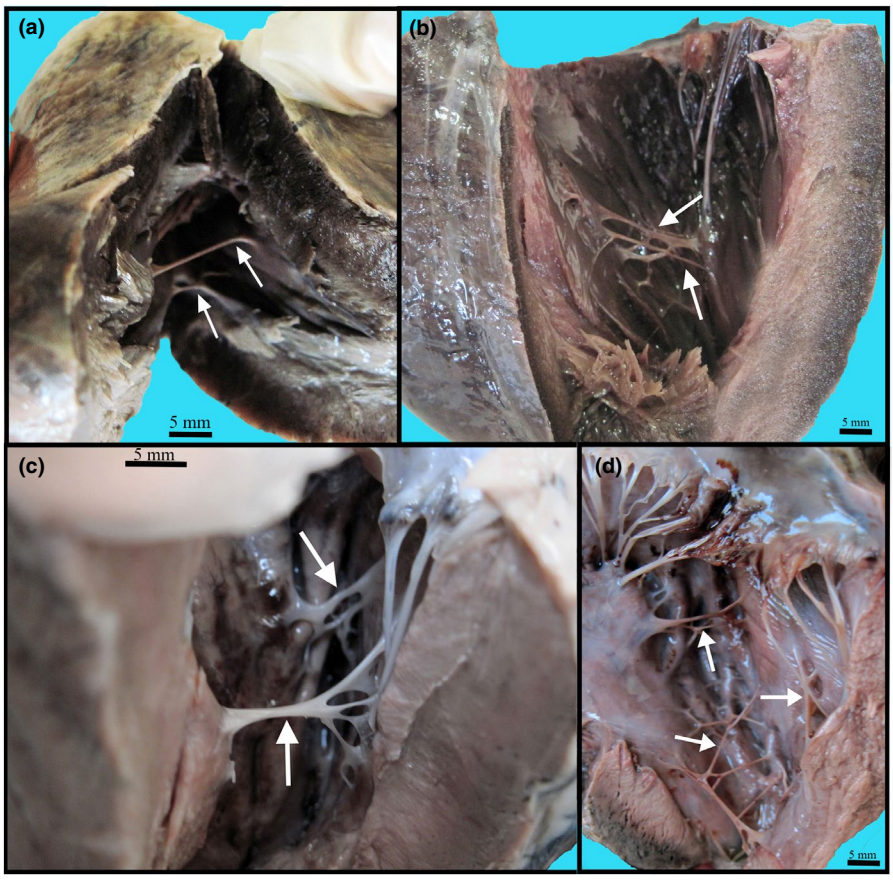


**FIGURE 2** (a–d) Left septomarginal trabeculae in the left ventricle of the Hatay Mountain gazelle hearts; arrows: tendinous chord

not have a real moderator band due to the placement of the anterior papillary muscle in the septum (Depreux et al., 1976; Truex & Warshaw, 1942). Ateş and Çakır (2010) also found that this muscle is located in the septum in guinea pigs and rabbits. In this study, it was shown that the anterior papillary muscle was located in the outer wall and the septal papillary muscle and posterior papillary muscles were located in the septum.

In studies on the human heart, it was stated that right septomarginal trabeculae were present in 17 out of 20 hearts (Raghavendra et al., 2013), 36 out of 38 hearts (Lee & Hur, 2019), 92 out of 100 hearts (Loukas et al., 2010), 284 out of 500 hearts (Truex & Warshaw, 1942), and all out of 220 hearts (Kosinski et al., 2010). Gulyaeva and Roshchevskaya (2012) reported that the right septomarginal trabecula was present in all out of 14 pig hearts, and they also found an additional thin septomarginal trabecula in one of these hearts. A study conducted (Truex & Warshaw, 1942) on the hearts of 100 cats, 12 each of monkeys, dogs, pigs, sheep, calves, and cattle found the right septomarginal trabeculae in all of the animal species except 51 cats, 5 monkeys, and 12 dogs. Although it is stated that there was no true right septomarginal trabecula in dogs (Depreux et al., 1976; Truex & Warshaw, 1942) and wolves (Depreux et al., 1976), its presence had been reported in all 39 (Cope, 2016a) and 30 (Bombonato et al., 2012) dog hearts in different studies. In the literature, right septomarginal trabeculae were detected in all out of 32 goats (Leao et al., 2010), 34 cattle (Nascimento et al., 2019), 10 camels (Ghonimi et al., 2014), 8 donkeys (Haligur & Dursun, 2009), 11 alpacas (Perez et al., 2018), 10 buffalos (Ghonimi et al., 2015), 10 guinea pigs (Ateş & Çakır, 2010), 10 rabbits (Ateş & Çakır, 2010), 7 wild boars (Ates et al., 2017), and in 131 out of 138 primates (Kosinski et al., 2013). It was reported that the number of right septomarginal trabeculae was one in humans (Arıncı & Elhan, 2014; Lee & Hur, 2019; Raghavendra et al., 2013), in pigs (Ates et al., 2017; Crick et al., 1998; Rocha et al., 2010), in buffalos (Ghonimi et al., 2015), in camels (Ghonimi et al., 2014), in cattle (Nascimento et al., 2019), in dogs (Bombonato et al., 2012; Cope, 2016b), in some primates (Kosinski et al., 2013), in goats (Leao et al., 2010), two in Pampas deers (Vazquez et al., 2019), and 1–3 in rabbits (Ateş & Çakır, 2010). In this study, there was one right septomarginal trabecula in all hearts examined.

Perez et al. (2018) found that the right septomarginal trabeculae extended obliquely in the ventricular cavity in the alpaca. In humans (Ravindran & Victor, 1982), it was determined that these trabeculae crossing the ventricular cavity were located vertically in 20 hearts. In a study (Ravindran & Victor, 1982), it was detected that the septomarginal trabeculae were short and thick or long and thin. Loukas et al. (2010) stated that septomarginal trabeculae were classified as 'short and thick' in 42 hearts, 'short and thin' in 24 hearts, 'long and thick' in 12 hearts, 'long and thin' in 14 hearts, and they could not be identified in 8 hearts. In another study (Lee & Hur, 2019), right septomarginal trabeculae were classified 'cylindrical' in seven, 'long and thin' in 15, 'wide and flat' in 14 hearts, and it was reported that they did not find this band in two hearts. It was stated that the right septomarginal trabeculae in bovine (Nascimento et al., 2019) were tubular fibromuscular structure. It was determined that septomarginal trabeculae were fleshy in camel (Ghonimi et al., 2014), in buffalo (Ghonimi et al.,

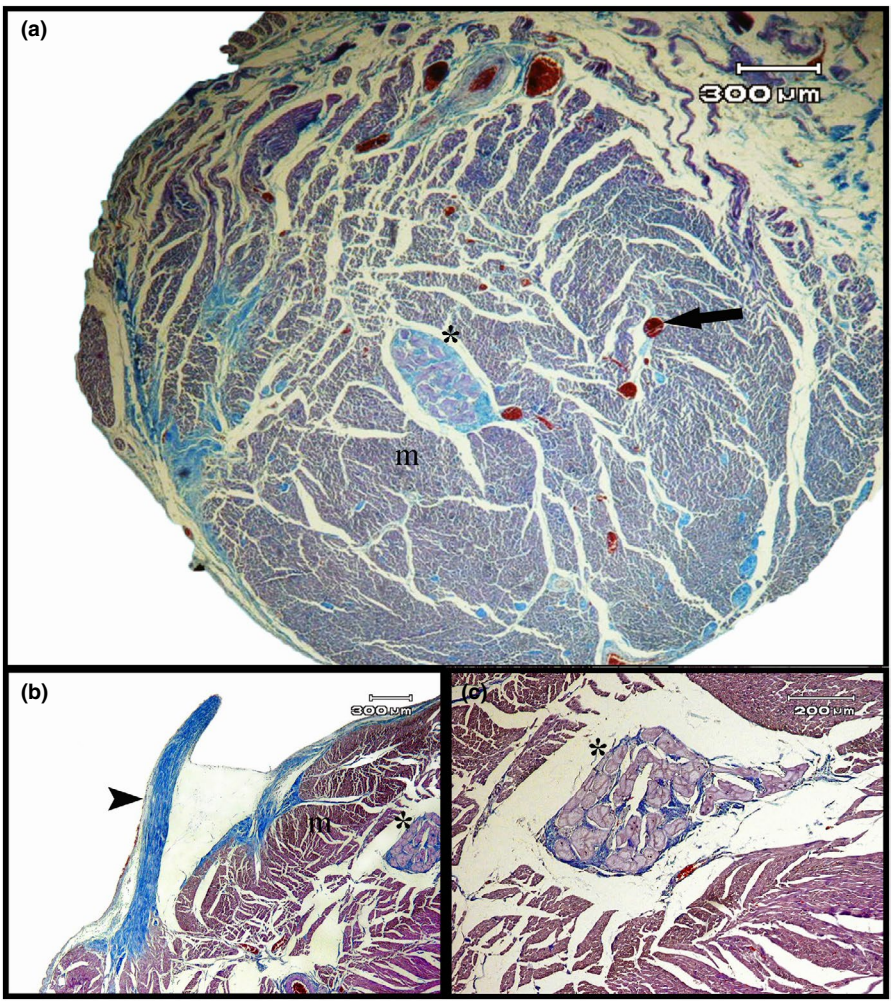


**FIGURE 3** (a–c) Histological appearance of the filamentous structures in the right septomarginal trabeculae; m: myocardial cells, asterisk: Purkinje fibres, arrow: blood vessel, arrowhead: tendinous chord

2015), and goats (Leao et al., 2010). In this study conducted in Hatay mountain gazelle, it was assessed that the septomarginal trabeculae extended horizontally or were slightly inclined in the ventricular cavity and these trabeculae were cylindrical and fleshy.

In the literature (Raghavendra et al., 2013), it was reported that the end of the septomarginal trabeculae attached to the anterior papillary muscle was single in three hearts and multiple in the remaining 14 hearts. In a study (Gulyaeva & Roshchevskaya, 2012), it was observed that in 3 of 14 pig hearts, the bifurcated end of septomarginal trabecula was attached to the outer wall, however, Ateş et al. (2017) stated that this bifurcated end was observed at the septum in wild boar. In a study on 30 dogs, Bombonato et al. (2012) found that 40% of the septomarginal trabeculae were unbranched, 33.33% were bifurcated, and 26.67% were branched. Bombonato et al. (2015) in a study on 30 horses showed that the ends of the septomarginal trabeculae attached to the outer wall were unbranched in 13.33%, bifurcated in 26.67%, tripled in 16.67%, quadrupled in 10%, multibranched in 16.67%, and it was stated that 16.67% of them were irregular. In the study conducted by Cope (2016b) on 39 dogs, the septomarginal trabecula was single in 17.95% of hearts, 'y' shaped in 2.56%, 3 or 4 branched networks in 28.21%, and 5 or more branched networks in 51.28%. In another study (Leao et al., 2010), it was reported that the septomarginal trabeculae were unbranched in 30 goat hearts and were bifurcated in 2 goat hearts. In a study of bovine hearts (Nascimento et al., 2019), it was reported that the end of the septomarginal trabeculae attached to the outer wall was single in 33 hearts and was bifurcated in one heart and trabeculae were in curved form, sinuous form, or arcuate form. In our study, all septomarginal trabeculae were unbranched.

Ravindran and Victor (1982) found that in a heart without anterior papillary muscle, one tendinous chord originating from the middle part of the septomarginal trabecula was attached to the anterior cusp, and in another heart, there was a false tendinous chord attached to the septomarginal trabecula, and in another heart, two papillary muscles originated from the septomarginal trabecula. In a literature (Leao et al., 2010), the researchers mentioned the presence of a false tendinous chord connecting the lower edge of the septomarginal trabeculae to the septum in 6 goat hearts, and a tendinous chord connecting the upper edge of the septomarginal trabeculae to the septal cusp in 20 hearts. In this study, in one of the two hearts with prominent septal papillary muscle, one tendinous chord originating from the moderator band was observed to attach to the septal cusp. In the other heart, three tendinous chords originating from the moderator band were detected. Two of these chords were attached to the anterior cusp and one to the septal cusp.

The lengths of right septomarginal trabeculae were 15–24 mm in sheep, 20–30 mm in calves (Truex & Warshaw, 1942), 13–26 mm in goats (Leao et al., 2010), and 20.16–47.63 mm in cattle (Nascimento

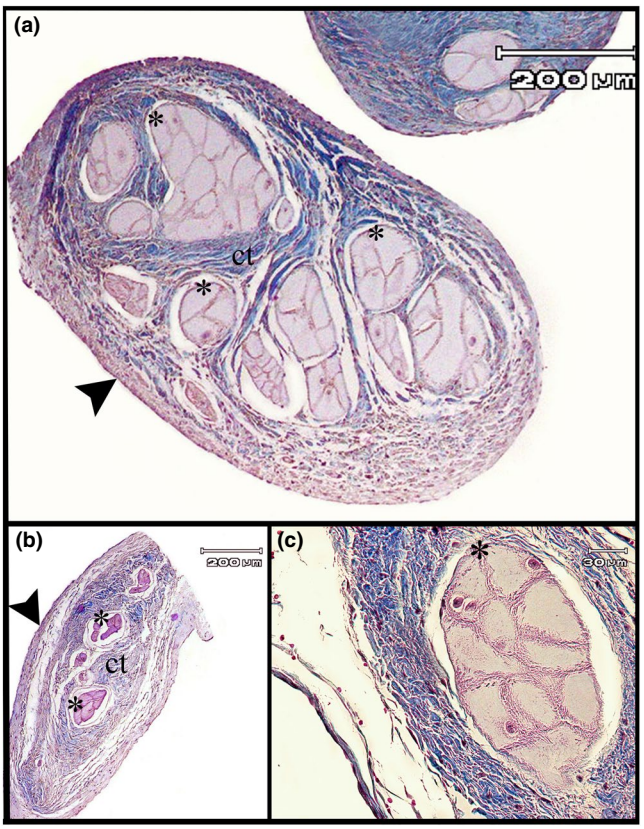


FIGURE 4 (a–c) Histological appearance of the filamentous structures in the left septomarginal trabeculae; asterisks: Purkinje fibres, ct: connective tissue, arrowheads: connective tissue sheath

et al., 2019). The thicknesses of these bands were 2–4 mm in sheep, 1–7 mm in calves (Truex & Warshaw, 1942), and 5 mm in goats (Leao et al., 2010). In our study, it was determined that the lengths of the right septomarginal trabeculae were 12–17 mm, and the thicknesses were 3–4 mm.

In certain studies, it was reported that left septomarginal trabeculae were present in the hearts of camel (Ghonimi et al., 2014), domestic pig (Gulyaeva & Roshchevskaya, 2012), rhinoceros (Erdoğan et al., 2014), donkey (Haligur & Dursun, 2009), rabbit, and guinea pig (Ateş & Çakır, 2010). It was stated that these structures were 2 in camels, 1–5 in donkeys, a few in pigs and rhinoceros, and 1–3 in rabbits and guinea pigs. In the literature (Gerlis et al., 1984), the rates of septomarginal trabeculae in the left ventricle were found to be 48% in humans, 86% in pigs, 92% in cattle, and 100% in sheep, horses, cats, and dogs. Deniz et al. (2004) reported these rates as 47% in humans, 77% in dogs, 92% in sheep, and 88% in goats. It was stated that the thickness of the left trabeculae was around 1–3 mm (Deniz et al., 2004; Gulyaeva & Roshchevskaya, 2012). The lengths of these structures were measured 6–31 mm in sheep and 7–37 mm in goats (Deniz et al., 2004). In this study, left septomarginal trabeculae were found in all hearts examined, including 2 trabeculae in three hearts and 3 trabeculae in one heart. The thicknesses of the trabeculae were between 0.5 and 1 mm and their lengths were between 6 and 15 mm. In the Hatay mountain gazelle, as in other ruminants (Deniz et al., 2004; Gerlis et al., 1984), these structures were frequently found in the left ventricle.

Ansari et al. (1999) reported that the moderator bands located in both the right and left ventricle of the sheep heart contain Purkinje fibres. According to Özbağ et al. (2003), many Purkinje cells are determined in the false tendinous chords belonging to the left ventricles of sheep and goat hearts. The structure that Özbağ et al. (2003) named false tendinous chord is the same structure as the moderator band in mountain gazelle. When compared with both studies, the presence of Purkinje cells in the moderator bands of both the left and right ventricles of mountain gazelle is seen as a similarity between sheep and goat and mountain gazelle. Deniz et al. (2004) showed that the left trabeculae of sheep and goats were mainly composed of fibrous connective tissue and conductive tissue in sheep and goats. In the same study, although cardiac muscle and blood vessels were detected in approximately 20% of the sheep, no cardiac muscle could be detected in goats. Since the heart muscle was not found in the samples examined in the study, it is thought that the left septomarginal trabecula of the mountain gazelle has a similar structure with all the goats and 80% of the sheep. In the literature (Jensen et al., 1978), it was stated that the cattle and goat moderator band contained Purkinje fibres in bundles of 1–5 cells, and these fibres were to a certain extent surrounded by a connective tissue sheath. In our study, a similarity was observed with the moderator band of mountain gazelle compared with cattle and goats in terms of cell number.

Nascimento et al. (2019) reported that the right septomarginal trabeculae of cattle generally consist of cardiac muscle, connective tissue, Purkinje fibres and vascular tissue and the middle part of the trabeculae are filled with cardiac muscle cells and vascular tissue. When the tissue content was evaluated according to the thickness of the trabeculae examined, it was reported that the connective tissue in thin trabeculae and cardiac muscle in thick trabeculae were more dominant. In this respect, the right septomarginal trabeculae of gazelles appear to have histological features similar to thick right septomarginal trabeculae of cattle. However, in two samples taken from mountain gazelles, the Purkinje fibre community were in the centre of the trabecula, unlike cattle.

In a study examining the right ventricles of buffaloes (Ghonimi et al., 2015), it was shown that the moderator band consists of two main parts: the endocardium in the periphery and the myocardium in the centre. In this study, it was reported that the Purkinje bundle surrounded by a highly vascularized loose connective tissue was in the subendocardial layer. Ghonomi et al. (2014) reported that two types of modified muscle cells, which are considered as the developmental stages of Purkinje fibres were found in the subendocardial region of the moderator bands in camels. They have found that Purkinje fibres filled the centre of the moderator band between the heart muscle bundles and in the form of fibres. When the findings of mountain gazelle are compared with the findings observed in buffalo and camel, it comes to mind that mountain gazelle has different structural features in terms of both moderator bands.

As a result, one right septomarginal trabecula was identified in each of the samples. Three of the samples had two left septomarginal

trabeculae and one sample had three left septomarginal trabeculae. Although the number of materials is not high due to being a protected species, our findings show that these structures are stable in both the right and left ventricles. When the right and left trabeculae were compared, in terms of shape, length and thickness, it was determined that the diversity was greater in the left trabeculae. In addition, the presence of tendinous chords originating from the right trabeculae has been previously mentioned in humans (Ravindran & Victor, 1982) and goats (Leao et al., 2010), and the presence of these tendinous chords has been visually demonstrated in our study as well as in the human study. Histologically, the presence of connective tissue and Purkinje fibres was detected in both septomarginal trabeculae. In addition, myocardial cells were found only in the right septomarginal trabecula. In the literature (Barber et al., 2019; Çelebi et al., 2014; Kervancioglu et al., 2003; Koie et al., 2007), septomarginal trabeculae containing Purkinje fibres are frequently cited as the source of arrhythmias, cardiac murmurs, and premature beats in structural heart diseases. In addition, it has been reported that arrhythmias occur because of atrophy of Purkinje cells in myocarditis cases of foot and mouth disease, which is a common disease of ruminants (Mahadappa et al., 2021). Due to the association of Purkinje and myocardial cells with such diseases or structural disorders, it is thought that a more detailed examination of the anatomical and histological structure of septomarginal trabeculae will contribute to pathological and clinical studies.

## ACKNOWLEDGEMENTS

We thank Research Assistant İpek Erdem for her valuable contributions. We would also like to thank the Academic Writing and Translation Support Coordinatorship of Hatay Mustafa Kemal University for the English revision of the manuscript.

## CONFLICT OF INTEREST

All authors declare that there is no conflict of interest.

## DATA AVAILABILITY STATEMENT

The data that support the findings of this study (Figures 1-4) are available from the corresponding author (Erdem, B.) upon reasonable request.

## ORCID

*Baran Erdem* https://orcid.org/0000-0002-3319-6586
*Tolga Tutar* https://orcid.org/0000-0002-2413-085X
*Lutfi Takci* https://orcid.org/0000-0002-8865-8186
*Yeşim Akaydin Bozkurt* https://orcid.org/0000-0001-8128-1411
*Sevinç Ateş* https://orcid.org/0000-0002-8381-0038

## REFERENCES

Abdulla, A. K., Frustaci, A., Martinez, J. E., Florio, R. A., Somerville, J., & Olsen, E. G. J. (1990). Echocardiography and pathology of left-ventricular false tendons. *Chest*, *98*(1), 129–132. https://doi.org/10.1378/chest.98.1.129

Ansari, A., Ho, S. Y., & Anderson, R. H. (1999). Distribution of the Purkinje fibres in the sheep heart. *The Anatomical Record*, *254*(1), 92–97. https://doi.org/10.1002/(SICI)1097-0185(19990101)254:1<92:AID-AR12>3.0.CO;2-3

Arıncı, K. & Elhan, A. (2014). Anatomi: kemikler, eklemler, kaslar, iç organlar (1. cilt) Ankara, Güneş Tıp Kitabevleri.

Armiger, L. C., Urthaler, F., & James, T. N. (1979). Morphological changes in the right ventricular septomarginal trabecula (false tendon) during maturation and ageing in the dog heart. *Journal of Anatomy*, *129*(4), 805–817.

Ateş, S., & Çakır, A. (2010). Yeni Zelanda tavşanı ve kobayda kalp kapaklarının karşılaştırmalı makro anatomisi. *Ankara Üniversitesi Veteriner Fakültesi Dergisi*, *57*(3), 145–150. https://doi.org/10.1501/Vetfak_0000002367

Ates, S., Karakurum, E., Takci, L., Basak, F., & Kurtul, I. (2017). Morphology of the atrioventricular valves and related intraventricular structures in the wild pig (Sus scrofa). *Folia Morphologica*, *76*(4), 650–659. https://doi.org/10.5603/FM.a2017.0051

Barber, M., Chinitz, J., & John, R. (2019). Arrhythmias from the right ventricular moderator band: Diagnosis and management. *Arrhythmia & Electrophysiology Review*, *8*(4), 294–299. https://doi.org/10.15420/aer.2019.18

Bombonato, P., Agreste, F., Nogueira, K., Santos, A., Vianna, A., & Lima, E. (2015). Stereometry study of septomarginal trabecula in equines. *Journal of Veterinary Advances*, *5*(4), 680–684. https://doi.org/10.5455/jva.20150417024416

Bombonato, P., Mariana, A. N. B., Borelli, V. F. A., Nascimento, L. G., & Leonardo, A. S. (2012). Morphometric study of trabecula septomarginalis in dogs. *Ars Veterinaria*, *28*(4), 250–254. https://doi.org/10.15361/2175-0106.2012v28n4p250-254

Çelebi, Ö. Ö., Çelebi, S., & Gülel, O. (2014). Sol Ventrikülde Mid-Kaviter Gradiyente Neden Olan Yalancı Tendon. *Koşuyolu Kalp Dergisi*, *17*(2), 138–139. https://doi.org/10.4274/khj.5184

Cope, L. A. (2016a). Atypical chordae tendineae of the canine (canis familiaris) right atrioventricular valve. *Anatomia, Histologia, Embryologia*, *45*(6), 485–489. https://doi.org/10.1111/ahe.12231

Cope, L. A. (2016b). Morphological variations in the canine (canis familiaris) right ventricle trabecula septomarginalis dextra and a proposed classification scheme. *Anatomia, Histologia, Embryologia*, *45*(6), 437–442. https://doi.org/10.1111/ahe.12217

Crick, S. J., Sheppard, M. N., Ho, S. Y., Gebstein, L., & Anderson, R. H. (1998). Anatomy of the pig heart: Comparisons with normal human cardiac structure. *Journal of Anatomy*, *193*(Pt 1)(1), 105–119. https://doi.org/10.1046/j.1469-7580.1998.19310105.x

Deniz, M., Kilinc, M., & Hatipoglu, E. S. (2004). Morphologic study of left ventricular bands. *Surgical and Radiologic Anatomy*, *26*(3), 230–234. https://doi.org/10.1007/s00276-003-0212-0

Denk, H., Künzele, H., Plenk, H., Rüschoff, J., & Sellner, W. (1989). *Romeis mikroskopische technik (17., neubearb. Aufl. ed.)*. Urban u. Schwarzenberg: Springer Spektrum.

Depreux, R., Mestdagh, H., & Houcke, M. (1976). Comparative morphology of the trabecula septomarginalis in terrestrial mammals. *Anatomischer Anzeiger*, *139*(1–2), 24–35.

Erdoğan, S., Lima, M., & Pérez, W. (2014). Inner ventricular structures and valves of the heart in white rhinoceros (*Ceratotherium simum*). *Anatomical Science International*, *89*(1), 46–52. https://doi.org/10.1007/s12565-013-0199-5

Evans, H. E., & De Lahunta, A. (2013). *Miller's anatomy of the dog*, 4th ed. Elsevier Health Sciences.

Gerlis, L. M., Wright, H. M., Wilson, N., Erzengin, F., & Dickinson, D. F. (1984). Left ventricular bands. A normal anatomical feature. *British Heart Journal*, *52*(6), 641–647. https://doi.org/10.1136/hrt.52.6.641

Ghonimi, W., Abuel-Atta, A. A., Bareedy, M. H., & Balah, A. (2014). Gross and microanatomical studies on the moderator bands (septomarginal trabecula) in the heart of mature Dromedary camel (Camelus dromedarius). *Journal of Advanced Veterinary and Animal Research*, *1*(2), 24–31. https://doi.org/10.5455/javar.v1i2p24-31

Ghonimi, W., Elbaz, A., Ibrahim, L., Khair, N., Emam, H., & Hellal, A. (2015). Moderator bands (Trabecula septomarginalis) of mature buffalo (*Bos bubalis* L.) with special emphasis on the structure and

distribution of the Purkinje cardiomyocytes: Histological and histochemical. *Cell and Developmental Biology*, *4*(3), 165. https://doi.org/10.4172/2168-9296.1000165

Gulyaeva, A. S., & Roshchevskaya, I. M. (2012). Morphology of moderator bands (septomarginal trabecula) in porcine heart ventricles. *Anatomia, Histologia, Embryologia*, *41*(5), 326–332. https://doi.org/10.1111/j.1439-0264.2012.01139.x

Haligur, A., & Dursun, N. (2009). Morphological and morphometric investigation of the musculus papillaris and cordae tendineae of the donkey (*Equus asinus* L.). *Journal of Animal and Veterinary Advances*, *8*(4), 726–733.

Jensen, H., Holtet, L., & Hoen, R. (1978). Nerve-Purkinje fiber relationship in the moderator band of bovine and caprine heart. *Cell and Tissue Research*, *188*(1), 11–18. https://doi.org/10.1007/BF00220511

Kervancioglu, M., Ozbag, D., Kervancioglu, P., Hatipoglu, E. S., Kilinc, M., Yilmaz, F., & Deniz, M. (2003). Echocardiographic and morphologic examination of left ventricular false tendons in human and animal hearts. *Clinical Anatomy*, *16*(5), 389–395. https://doi.org/10.1002/ca.10152

Koie, H., Hara, A., Sakai, M., Takiyama, N., & Uechi, M. (2007). Clinical evaluation of left ventricular moderator band in 12 dogs. *The Journal of Veterinary Medical Science*, *69*(9), 965–967. https://doi.org/10.1292/jvms.69.965

Kosinski, A., Kozlowski, D., Nowinski, J., Lewicka, E., Dabrowska-Kugacka, A., Raczak, G., & Grzybiak, M. (2010). Morphogenetic aspects of the septomarginal trabecula in the human heart. *Archives of Medical Science*, *6*(5), 733–743. https://doi.org/10.5114/aoms.2010.17089

Kosinski, A., Zajaczkowski, M., Kuta, W., Kozlowski, D., Szpinda, M., & Grzybiak, M. (2013). Septomarginal trabecula and anterior papillary muscle in primate hearts: Developmental issues. *Folia Morphologica*, *72*(3), 202–209. https://doi.org/10.5603/fm.2013.0034

Leao, C. R., Pacha, D. L., Cyriaco, T., da Silva, C., Wafae, N., Pereira, H. M., & Ruiz, C. R. (2010). Anatomy of the septomarginal trabecula in goat hearts. *Italian Journal of Anatomy and Embryology*, *115*(3), 229–234.

Lee, J. Y., & Hur, M. S. (2019). Morphological classification of the moderator band and its relationship with the anterior papillary muscle. *Anatomy & Cell Biology*, *52*(1), 38–42. https://doi.org/10.5115/acb.2019.52.1.38

Lerman, B. B., Cheung, J. W., Ip, J. E., Liu, C. F., Thomas, G., & Markowitz, S. M. (2018). Mechanistic subtypes of focal right ventricular tachycardia. *Journal of Cardiovascular Electrophysiology*, *29*(8), 1181–1188. https://doi.org/10.1111/jce.13505

Loukas, M., Klaassen, Z., Tubbs, R. S., Derderian, T., Paling, D., Chow, D., Patel, S., & Anderson, R. H. (2010). Anatomical observations of the moderator band. *Clinical Anatomy*, *23*(4), 443–450. https://doi.org/10.1002/ca.20968

Loukas, M., Louis, R. G. Jr, Black, B., Pham, D., Fudalej, M., & Sharkees, M. (2007). False tendons: An endoscopic cadaveric approach. *Clinical Anatomy*, *20*(2), 163–169. https://doi.org/10.1002/ca.20347

Mahadappa, P., Mahendran, K., Winter, R. L., Umapathi, V., Krishnaswamy, N., Gopalakrishnan, A., Rao, S., Gangaiah, M., Kumar, S., Patel, B., Gautam, N., Hegde, R., Dechamma, H. J., & Sanyal, A. (2021). Characterization of arrhythmias, evaluation of cardiac biomarkers and their association with survival in calves suffering from foot-and-mouth disease. *Journal of Veterinary Cardiology*, *36*, 64–76. https://doi.org/10.1016/j.jvc.2021.04.002

Nascimento, S. R. R., Ruiz, C. R., & de Oliva, S. U. (2019). Histological and anatomical variations of septomarginal trabecula in bovine hearts. *Anatomia, Histologia, Embryologia*, *48*(3), 228–233. https://doi.org/10.1111/ahe.12427

International Committee on Veterinary Gross Anatomical Nomenclature (2017). Nomina Anatomica Veterinaria (NAV), 6th ed. Editorial Committee Hanover (Germany), Ghent (Belgium), Columbia, MO (U.S.A.), Rio de Janeiro (Brazil).

Noyan, A. (1998). Yaşamda ve hekimlikte fizyoloji (7. Baskı) Ankara, Meteksan.

Özbağ, D., Kervancıoglu, P., & Kervancıoglu, M. (2002). Sol Ventrikülde Yalancı Chordae Tendineae. *Sendrom*, *14*, 85–89.

Özbağ, D., Kervancıoğlu, P., Saruhan, B., Taşdemir, S., & Yılmaz, F. (2003). Farklı türlerde sol ventriküldeki gerçek chordae tendineae ile yalancı chordae tendineae'nın morfolojik ilişkisinin karşılaştırmalı olarak incelenmesi. *Turkish Journal of Veterinary and Animal Sciences*, *27*(1), 133–140.

Özer, A. (2008). *Veteriner özel histoloji*. Dora Yayıncılık.

Özkan, M. (2020). Ülkemizdeki iki ceylan türünden biri: Hatay dağ ceylanı. *Türk Tarım Ve Orman Dergisi*, *260*, 86–87. Retrieved from http://www.turktarim.gov.tr/EDergi/260/mobile/html5forpc.html

Padala, S. K., Cabrera, J. A., & Ellenbogen, K. A. (2021). Anatomy of the cardiac conduction system. *Pacing and Clinical Electrophysiology*, *44*(1), 15–25. https://doi.org/10.1111/pace.14107

Perez, W., Mendez, V., Vazquez, N., Navarrete, M., & Konig, H. E. (2018). Gross anatomy of the heart of the alpaca (*Vicugna pacos*, Linnaeus 1758). *Anatomia, Histologia, Embryologia*, *47*(2), 110–118. https://doi.org/10.1111/ahe.12327

Philip, S., Cherian, K. M., Wu, M. H., & Lue, H. C. (2011). Left ventricular false tendons: Echocardiographic, morphologic, and histopathologic studies and review of the literature. *Pediatrics and Neonatology*, *52*(5), 279–286. https://doi.org/10.1016/j.pedneo.2011.06.007

Raghavendra, A., Kumar, A., Tarvadi, P., & Harsha, C. (2013). Anatomical study of the moderator band. *Journal of Health and Allied Sciences*, *3*(04), 78–81. https://doi.org/10.1055/s-0040-1703707

Ravindran, P., & Victor, S. (1982). The moderator band. *Indian Journal of Thoracic and Cardiovascular Surgery*, *1*(1), 15–21. https://doi.org/10.1007/BF02664141

Rocha, H., Eliziario, L. F., Wafae, G. C., Silva, N. C., Ruiz, C. R., & Wafae, N. (2010). Anatomy of the septomarginal trabecula in Landrace pig hearts. *Morphologie*, *94*(305), 26–29. https://doi.org/10.1016/j.morpho.2010.03.004

Sadek, M. M., Benhayon, D., Sureddi, R., Chik, W., Santangeli, P., Supple, G. E., Hutchinson, M. D., Bala, R., Carballeira, L., Zado, E. S., Patel, V. V., Callans, D. J., Marchlinski, F. E., & Garcia, F. C. (2015). Idiopathic ventricular arrhythmias originating from the moderator band: Electrocardiographic characteristics and treatment by catheter ablation. *Journal of the Heart Rhythm Society and the Cardiac Electrophysiology Society*, *12*(1), 67–75. https://doi.org/10.1016/j.hrthm.2014.08.029

Sathyamoorthy, O., & Ramesh, G. (2008). Microanatomical studies on the moderator band (trabecula septomarginalis) of horses (Equus caballus). *Journal of Veterinary and Animal Sciences*, *39*, 33–35.

Silbiger, J. J. (2013). Left ventricular false tendons: Anatomic, echocardiographic, and pathophysiologic insights. *The Journal of the American Society of Echocardiography*, *26*(6), 582–588. https://doi.org/10.1016/j.echo.2013.03.005

Truex, R. C., & Warshaw, L. J. (1942). The incidence and size of the moderator band in man and in mammals. *The Anatomical Record*, *82*(3), 361–372. https://doi.org/10.1002/ar.1090820309

Vazquez, N., Dos Santos, D., Pérez, W., Artigas, R., & Sorriba, V. (2019). Gross anatomy of the heart of Pampas deer (*Ozotoceros bezoarticus*, Linnaeus 1758). *Journal of Morphological Sciences*, *36*(3), 190–195. https://doi.org/10.1055/s-0039-1692159

**How to cite this article:** Erdem, B., Tutar, T., Takci, L., Akaydin Bozkurt, Y., & Ateş, S. (2021). Morphology of septomarginal trabeculae in Hatay mountain gazelle (Gazella gazella). *Anatomia, Histologia, Embryologia*, 00, 1–8. https://doi.org/10.1111/ahe.12777